



IJABBR- 2014- eISSN: 2322-4827

International Journal of Advanced Biological and Biomedical Research

Journal homepage: www.ijabbr.com



Original Article

Pathological Evaluation of Essential Amino Acid Injection for Chicken Embryonated Eggs

Hadi Tavakkoli^{1*}, Sajedah Salandari²

¹Department of Clinical Science, Faculty of Veterinary Medicine, Shahid Bahonar University of Kerman, Kerman, Iran

²Graduate student, Faculty of Veterinary Medicine, Shahid Bahonar University of Kerman, Kerman, Iran

ARTICLE INFO

Article history:

Received: 09 Sep, 2014

Revised: 27 Oct, 2014

Accepted: 18 Nov, 2014

ePublished: 30 Dec, 2014

Key words:

Chicken

Embryo

Histopathology

Methionine

ABSTRACT

Objective: The objective of this study was to investigate the pathological alterations of methionine for chicken embryo. In recent years, amino acids are used in veterinary medicine for many purposes. They injected into hatching eggs to increase chick body weight and performance at hatch, but the adverse effects of amino acids have always been a major concern. There is scant information available about the pathological alterations of amino acids in the chicken embryonated eggs. **Methods:** Fertile chicken eggs were divided into two equal treatment groups as follows: phosphate buffered saline-injected group and methionine-injected group whose individuals were injected with a methionine solution at a dosage of 10 mg per Kg egg-weight. Embryos were re-incubated post-treatment and allowed to develop until day 18 after which; they were examined for macroscopic and microscopic lesions. **Results:** The germination of inoculated seed was significantly reduced, germ tubes of microconidia penetrated all parts of the thick, complex seed testa, and seed contents were destroyed. Pathogenicity tests indicated that *F. solani* caused lesions of black soft rot and complete deterioration within 5-7 days (100%). They also attacked *Orobanch* seeds, arresting their germination and causing maceration of non-germinated and germinated seeds after 5-7 days of incubation. This is the first investigation of the effects of *F. solani* on host plant interactions with broomrape in melon.

1. INTRODUCTION

Different stress factors resulted in significant economic losses in the poultry industry. Methods include development in the management protocols and using different types of nutrients were applied to alleviate economic losses in this industry (King' Ori 2011; Surai et al. 2012; Mosallanejad et al. 2014b). Amino acids have been used across the globe for many years. Today, they are used on a large scale and are applied for different purposes (Li et al. 2011; Zhou et al. 2012; Fernstrom 2013; Meijer et al. 2014). In veterinary medicine, they are used to prevent disease, cure animals and birds, or as a feed additive to promote growth (Rutherford et al.

2012; Rezaei et al. 2013; Wu 2013; Wu et al. 2013; Zhai et al. 2013).

Methionine is an α -amino acid that is one of two sulfur-containing proteinogenic amino acids (Adams 2001; Boothe 2011). Methionine is one of only two amino acids encoded by a single codon (AUG) in the standard genetic code (tryptophan, encoded by UGG, is the other). In reflection to the evolutionary origin of its codon, the other AUN codons encode isoleucine, which is also a hydrophobic amino acid. In the mitochondrial genome of several organisms, including metazoa and yeast, the codon AUA also encodes for methionine. Methionine is used to prevent liver damage in acetaminophen poisoning. It is also used for increasing the acidity of urine, treating liver disorders, and improving wound

*Corresponding Author: Hadi Tavakkoli, Department of Clinical Science, Faculty of Veterinary Medicine, Shahid Bahonar University of Kerman, Kerman, Iran (Tavakkoli@uk.ac.ir)

healing. Other uses include treating depression, alcoholism, allergies, asthma, copper poisoning, radiation side effects, schizophrenia, drug withdrawal, and Parkinson's disease (Golan et al. 2011).

In the veterinary medicine, methionine is one of ten so-called "essential" amino acids that must be supplied in the diet (Adams 2001). Methionine is a principle supplier of sulfur to the body and helps prevent disorders of the hair, skin and nails. It lowers plasma cholesterol by increasing hepatic production of lecithin and reduces hepatic fat. It is essential for absorption, transportation, and bioavailability of selenium and zinc in the body. Methionine also protects the kidneys; is a natural chelating agent for heavy metals; regulates the formation of ammonia; and helps create ammonia-free urine. Methionine may be available as a prescription drug or as an over-the-counter medication. It also injected into hatching eggs to increase chick body weight and performance at hatch (Adams 2001; Golan, Tashjian et al. 2011; Tripathi 2013).

Adverse effects of amino acids have always been a major concern. There is little research in the literature describing the pathological effects of amino acids on the developing bird embryos, and further studies still need to be undertaken to determine the safety, toxicity and teratogenic potential of amino acids. On the other hand, the application of amino acids for in ovo administration in the bird's egg still needs to be justified. In this regard, in the present study, we investigated using of methionine solution for in ovo administration in embryonated chicken eggs. We believe that results in this study will contribute to our better understanding of safety and pathological effects of methionine on the bird embryos.

2. MATERIALS AND METHODS

2.1. Hatching eggs

Fertile chicken eggs (Ross 308) with the average egg-weight of 50 ± 2 g and with the same age were purchased from a local breeder farm. In this farm, birds were kept and grown up under the standard condition of breeding.

2.2. Drugs

Methionine powder was obtained from the Degussa Company, South Africa. It was diluted in phosphate buffered saline solution and sterile with 0.22 μ m syringe filter. A volume of 0.5 ml of phosphate buffered saline solution with 10 mg methionine was inoculated per Kg egg-weight.

2.3. Experimental protocol

Eggs were incubated at 37.5°C and 55% relative humidity. The eggs were randomly assigned to two equal treatment groups, 10 eggs each, as follows: group 1: phosphate buffered saline injected group, embryonated eggs injected with sterile phosphate buffered saline of 0.5

ml/egg into the yolk sac. On day 4 of incubation, the eggs of group 2 treated with a methionine solution at a dosage of 10 mg methionine per Kg egg-weight. Embryos received treatment by direct injection into the yolk sac according to the standard techniques (Hamburger 1942). Embryos were re-incubated post-treatment and allowed to develop. The viability of the embryos was checked throughout the incubation period by candling. All embryos were necropsied on day 18 of incubation and examined for macroscopic and microscopic lesions. The treatment protocols and procedures in this study were conducted according to local ethical guidelines, and were approved by the Animal Ethics Committee of the Research Council of Shahid Bahonar University, Iran.

2.4. Pathological examination

At the end of the experiment, on day 18, embryos were humanely killed by placing on ice and then the eggs were opened at the wider end (Jacobsen et al. 2012). After washing in normal saline solution, embryos were observed under stereomicroscope to study any gross abnormalities on the external body surface. The membranes and yolk sac were also inspected. Then, the tissues of embryos were dissected out and fixed in 10% neutral buffered formalin. Following routine preparation of tissues, serial sections of paraffin embedded tissues of 5 μ m thicknesses were cut using a microtome (Slee-Germany) and stained with hemotoxylin and eosin and studied under light microscope.

2.5. Statistical analysis

Statistical analysis was performed using SPSS version 20. The Chi-Square test was used to determine the significant differences in lesion occurrence between experimental groups. A P-value of <0.05 was considered as statistically significant.

3. RESULTS

3.1. Macroscopic results

The tissues of the embryos were normal in group 1. In methionine-injected group, group 2, there was not any gross abnormality in the tissues and external body surfaces (figure 1). The obtained tissue samples of these embryos were sent to the pathology laboratory.

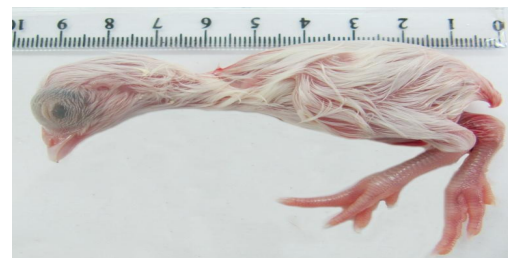


Fig. 1. The chicken embryo treated with the methionine solution into the yolk sac. The embryo is normal with no gross lesions.

3.2. Microscopic findings

Histopathological evaluation has been revealed that all organs were normal in group 1. In embryos of group 2, which received the methionine solution, all microscopic structures were also normal (figures 2-5).

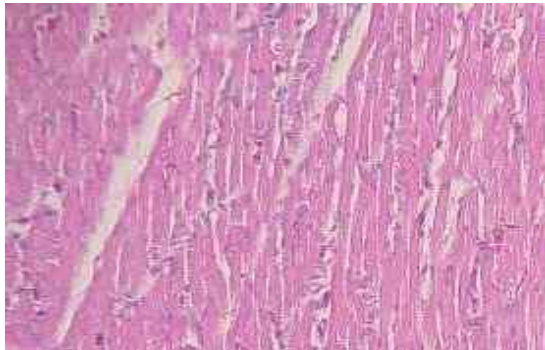


Fig. 2. Photomicrograph of the chicken embryo treated with the methionine solution into the yolk sac. A normal structure of the heart is seen. $\times 100$ H&E

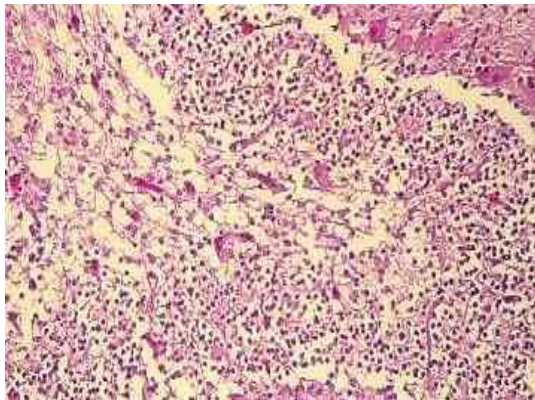


Fig. 3. Photomicrograph of the chicken embryo treated with the methionine solution into the yolk sac. The normal structure of the cerebellum is seen. $\times 400$ H&E

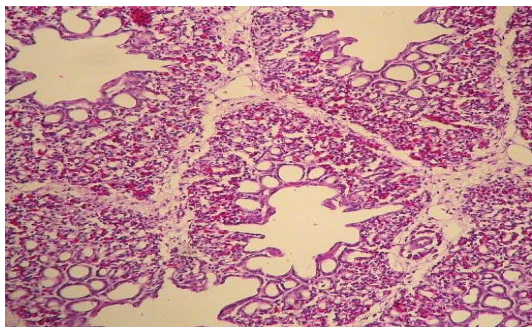


Fig. 4. Photomicrograph of the chicken embryo treated with the methionine solution into the yolk sac. A normal structure of the lung is seen. $\times 100$ H&E

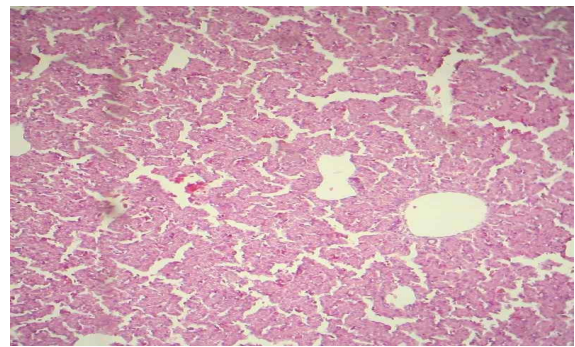


Fig. 5. Photomicrograph of the chicken embryo treated with the methionine solution into the yolk sac. The normal structure of the liver is seen. $\times 100$ H&E

4. DISCUSSION

The poultry industry has experienced tremendous development and expansion during the past ten years. On the other hand, different stress factors are an important and significant hazard for poultry health and cause serious economic losses to this industry. For many years, researchers have been using various additive compounds to restrict stress and enhance the performance of different poultry species, including young chicken and broiler (Mountzouris et al. 2011; Gracia et al. 2013; Kogut et al. 2013; Oakley et al. 2014), (Bagherzadeh et al. 2012; Blake et al. 2013; Khosravifar et al. 2014; Swain et al. 2014), turkey (Czech et al. 2012; Ognik et al. 2012; Huff et al. 2013; Devreese et al. 2014), layers (Lim et al. 2011; Schwarz et al. 2011; Khan et al. 2013) and poultry breeder (Broekaert et al. 2012; Fulton 2012; Murakami et al. 2014).

Amino acids have an increased role as feed additives in the poultry industry. They injected into hatching eggs to increasing chick body weight and performance at hatch. Methionine belongs to the essential amino acids groups. It has been used successfully for several decades in many countries such as Canada, Spain, France, Austria, Polish, Denmark, Germany, Turkey, Africa, United States and China. In recent years, its use has increased rapidly in the Iranian poultry industry, but there is little information available about the pathological effects of injecting methionine solution into the bird's egg. Besides, determining the side effects of drugs on the development of bird embryo is a useful method for studying the biological properties of drugs. In the present study, we investigated the using and toxicity of methionine solution for in ovo administration in chicken egg. Lesions and organ injuries following administration were also inspected. Up to now, amino acids-egg-treatment has been examined and described in different situations (Al-Daraji et al. 2012; Gaafar et al. 2012; Kita et al. 2014). The results of these studies show that in ovo administration of amino acids may be an effective method to increase chick performance and body weight (Bhanja et al. 2014; Kita, R Ito et al. 2014; Li et al. 2014; Shafey et al. 2014). Dosage and the rout of injection can have an influence on

the outcome (Mosallanejad et al. 2014a; Tavakkoli et al. 2014a; Tavakkoli et al. 2014b). On the other hand, some injection sites that are present in fertile eggs at day 4 of incubation are the air cell and yolk sac. Injection drugs into the air cell of the egg is discontinued and is not suitable for breeding purposes because drastic mortality of embryos occur when eggs treat by this procedure (McCapes et al. 1975; Nascimento et al. 2005; Tavakkoli et al. 2104).

Our results obviously showed no gross abnormality in the tissues and external body surfaces of the chicken embryos exposed to methionine solution by yolk sac rout. Histopathological examination has also been revealed that all organs were normal in embryos. Therefore, these results suggest that the best methionine injection sites in ovo may be the yolk sac. Nevertheless, further efforts are needed to evaluate in ovo administration of various amino acids. In conclusion, based on macroscopic and microscopic findings, it is concluded that methionine solution can be used for the success of the in ovo-injection scheme with low toxicity to chicken embryo. In addition, the yolk sac is an appropriate site for injecting essential amino acids.

ACKNOWLEDGMENT

The authors wish to thank Mr. S. Hasanzadeh for his kind cooperation in slide preparation.

REFERENCES

Adams HR (2001). *Veterinary pharmacology and therapeutics*, Iowa State University Press.

Al-Daraji H, Al-Mashadani A, Al-Hayani W, Al-Hassani A, Mirza H (2012). Effect of in ovo injection with L-arginine on productive and physiological traits of Japanese quail. *S. Afr. J. Anim. Sci.* 42(2): 139-145.

Bagherzadeh KF, Karimi TM, Allameh A, Shariatmadari F (2012). A novel aflatoxin-binding *Bacillus* probiotic: Performance, serum biochemistry, and immunological parameters in Japanese quail. *Poult. Sci.* 91(8): 1846-1853.

Bhanja S, Sudhagar M, Goel A, Pandey N, Mehra M, Agarwal S, Mandal A (2014). Differential expression of growth and immunity related genes influenced by in ovo supplementation of amino acids in broiler chickens. *Czech J. Anim. Sci.* 59(9): 399-408.

Blake J, Hess J (2013). Performance of bobwhite quail fed different levels of protein and feed additive supplementation. *The Journal of Applied Poultry Research* 22(2): 314-318.

Boothe DM (2011). *Small animal clinical pharmacology and therapeutics*, Elsevier Health Sciences.

Broekaert N, Daeseleire E, Delezie E, Vandecasteele B, De Beer T, Van Poucke C (2012). Can the use of coccidiostats in poultry breeding lead to residues in vegetables? An experimental study. *J. Agric. Food Chem.* 60(50): 12411-12418.

Czech A, Ognik K, Grela E (2012). Efficacy of a mixture of synthetic antioxidant and protein-xanthophyll alfalfa concentrate in turkey hens feeding. *Archive Fur Geflugelkunde* 76(2): 105-112.

Devreese M, Girgis GN, Tran S-T, De Baere S, De Backer P, Croubels S, Smith TK (2014). The effects of feed-borne *Fusarium* mycotoxins and glucomannan in turkey poult based on specific and non-specific parameters. *Food Chem. Toxicol.* 63(69-75).

Fernstrom JD (2013). Large neutral amino acids: dietary effects on brain neurochemistry and function. *Amino Acids* 45(3): 419-430.

Fulton J (2012). Genomic selection for poultry breeding. *Animal Frontiers* 2(1): 30-36.

Gaafar KM, Selim SA (2012). Effect of in-ovo administration with two levels of amino acids mixture on the performance of Muscovy ducks. *Emirates J. Food Agri.* 25(1): doi: 10.9755/ejfa.v9725i9751.9666.

Golan DE, Tashjian AH, Armstrong EJ (2011). *Principles of pharmacology: the pathophysiologic basis of drug therapy*, Lippincott Williams & Wilkins.

Gracia MI, Sánchez J, Casabuena O, Wiemann M, Weber GM (2013). Effect of an Eubiotic feed additive on broiler performance in energy reduced diets. 19th European Symposium On Poultry Nutrition.

Hamburger V (1942). *A manual of experimental embryology*, University of Chicago Press Chicago:

Huff G, Huff W, Jalukar S, Oppy J, Rath N, Packialakshmi B (2013). The effects of yeast feed supplementation on turkey performance and pathogen colonization in a transport stress/*Escherichia coli* challenge. *Poult. Sci.* 92(3): 655-662.

Jacobsen ID, Große K, Hube B (2012). Embryonated Chicken Eggs as Alternative Infection Model for Pathogenic Fungi. *Host-Fungus Interactions*, Springer: 487-496.

Khan TA, Khan MN, Hasan R, Fatima H, Kousar E (2013). Effects of *Nigella sativa* (Black Seed) on Serum Levels of Urea and Uric Acid in Acetaminophen Induced Hepatotoxicity of Commercial Layer Chickens. *J. World's Poul. Res.* 3(4):

Khosravifar O, Ebrahimnezhad Y, Maheri-Sis N, Nobar R, Ghiasi-Galekandi J (2014). Effect of some medicinal

plants as feed additive on total coliform count of ileum in Japanese quails (*Coturnix coturnix japonica*). *Int. J. Biosci. (IJB)* 4(2): 211-220.

King'ori A (2011). Review of the factors that influence egg fertility and hatchability in poultry. *Int. J. Poult. Sci* 10(6): 483-493.

Kita K, R Ito K, Sugahara M, Kobayashi M, Makino R, Takahashi N, Nakahara H, Takahashi K, Nishimukai M (2014). Effect of In Ovo Administration of Branched-Chain Amino Acids on Embryo Growth and Hatching Time of Chickens. *J. Poult. Sci.* 11(5): 423-429.

Kogut MH, Genovese KJ, He H, Swaggerty CL, Jiang Y (2013). Modulation of Chicken Intestinal Immune Gene Expression by Small Cationic Peptides as Feed Additives during the First Week Posthatch. *Clin. Vaccine Immunol.* 20(9): 1440-1448.

Li X, Rezaei R, Li P, Wu G (2011). Composition of amino acids in feed ingredients for animal diets. *Amino Acids* 40(4): 1159-1168.

Li X, Sui W, Yan H, Jiang Q, Wang X (2014). The in ovo administration of l-trans pyrrolidine-2, 4-dicarboxylic acid regulates small intestinal growth in chicks. *Int. J. Anim. Biosci.* 8(10): 1677-1683.

Lim T-H, Lee D-H, Lee Y-N, Park J-K, Youn H-N, Kim M-S, Lee H-J, Yang S-Y, Cho Y-W, Lee J-B (2011). Efficacy of bacteriophage therapy on horizontal transmission of *Salmonella Gallinarum* on commercial layer chickens. *Avian Dis.* 55(3): 435-438.

McCapes RH, Yamamoto R, Ortmayer HB, Scott WF (1975). Injecting antibiotics into turkey hatching eggs to eliminate *Mycoplasma meleagridis* infection. *Avian Dis* 19(3): 506-514.

Meijer AJ, Lorin S, Blommaert EF, Codogno P (2014). Regulation of autophagy by amino acids and MTOR-dependent signal transduction. *Amino Acids* 1-27.

Mosallanejad S, Tavakkoli H, Derakhshanfar A, S S (2014a). Efficiency of the injection of trimethoprim/sulfamethoxazole solution on game bird embryonated-egg during the late stage of development. *Int. J. Adv. Biol. Biom. Res.* 2(5): 1553-1561.

Mosallanejad S, Tavakkoli H, Derakhshanfar A, S S (2014b). An experimental study of the systemic alteration of nitroimidazoles in the middle stage of embryonic development. *Int. J. Adv. Biol. Biom. Res.* 2(5): 1468-1474.

Mountzouris K, Paraskevas V, Tsirtsikos P, Palamidi I, Steiner T, Schatzmayr G, Fegeros K (2011). Assessment of a phytogetic feed additive effect on broiler growth

performance, nutrient digestibility and caecal microflora composition. *Anim. Feed Sci. Technol.* 168(3): 223-231.

Murakami A, Rodrigueiro R, Santos T, Ospina-Rojas I, Rademacher M (2014). Effects of dietary supplementation of meat-type quail breeders with guanidinoacetic acid on their reproductive parameters and progeny performance. *Poult. Sci.* 93(9): 2237-2244.

Nascimento ER, Pereira V, Nascimento M, Barreto M (2005). Avian mycoplasmosis update. *Revista Brasileira de Ciência Avícola* 7(1): 1-9.

Oakley BB, Buhr RJ, Ritz CW, Kiepper BH, Berrang ME, Seal BS, Cox NA (2014). Successional changes in the chicken cecal microbiome during 42 days of growth are independent of organic acid feed additives. *BMC Vet. Res.* 10(1): 282.

Ognik K, Krauze M (2012). Dietary supplementation of mannanoligosaccharides to turkey hens on their growth performance and antioxidant status in the blood. *S. Afr. J. Anim. Sci.* 42(4): 379-388.

Rezaei R, Wang W, Wu Z, Dai Z, Wang J, Wu G (2013). Biochemical and physiological bases for utilization of dietary amino acids by young pigs. *J Anim Sci Biotech* 4(7):

Rutherford S, Chung T, Thomas D, Zou M, Moughan P (2012). Effect of a novel phytase on growth performance, apparent metabolizable energy, and the availability of minerals and amino acids in a low-phosphorus corn-soybean meal diet for broilers. *Poult. Sci.* 91(5): 1118-1127.

Schwarz A, Gaulty M, Abel H, Daş G, Humburg J, Rohn K, Breves G, Rautenschlein S (2011). Immunopathogenesis of *Ascaridia galli* infection in layer chicken. *Dev. Comp. Immunol.* 35(7): 774-784.

Shafey T, Mahmoud A, Alsobayel A, Abouheif M (2014). Effects of in ovo administration of amino acids on hatchability and performance of meat chickens. *S. Afr. J. Anim. Sci.* 44(2): 123-130.

Surai P, Fisinin V (2012). The modern anti-stress technologies in poultry: from antioxidants to vitagenes. *Sel'skokhozyaistvennaya Biologiya. Agricul. Biol.* 4(2): 3-12.

Swain B, Naik P, Chakurkar E, Singh N (2014). Effect of biovet on performance, egg quality characteristics and hatchability in quail breeders. *Indian J. Anim. Res.* 48(3): 281-285.

Tavakkoli H, Derakhshanfar A, Noori Gooshki S (2014a). The effect of florfenicol egg-injection on embryonated chicken egg. *Int. J. Adv. Biol. Biom. Res.* 2(2): 496-503.

Tavakkoli H, Derakhshanfar A, Salandari S (2104). Investigation on the using of linco-spectin solution for in ovo administration in chicken embryo. Int. J. Adv. Biol. Biom. Res. 2(1): 110-116.

Tavakkoli H, Noori Gooshki S (2014b). The Effect of Doxycycline on the Viability of the Quail Embryo During Incubation Period. Int. J. Adv. Biol. Biom. Res. 2(8): 2390-2394.

Tripathi K (2013). Essentials of medical pharmacology, JP Medical Ltd.

Wu G (2013). Functional amino acids in nutrition and health. Amino Acids 45(3): 407-411.

Wu G, Wu Z, Dai Z, Yang Y, Wang W, Liu C, Wang B, Wang J, Yin Y (2013). Dietary requirements of "nutritionally non-essential amino acids" by animals and humans. Amino Acids 44(4): 1107-1113.

Zhai W, Peebles E, Zumwalt C, Mejia L, Corzo A (2013). Effects of dietary amino acid density regimens on growth performance and meat yield of Cobb× Cobb 700 broilers. J. App. Poult. Res. 22(3): 447-460.

Zhou Y, Yoon J (2012). Recent progress in fluorescent and colorimetric chemosensors for detection of amino acids. Chem. Soc. Rev. 41(1): 52-67.