



IJABBR- 2014- eISSN: 2322-4827

International Journal of Advanced Biological and Biomedical Research

Journal homepage: www.ijabbr.com



Original Article

In Ovo Injection of Triaminohexanoic Acid in Fowl: Gross Investigation

Seyede Saeedeh Mosallanejad^{1*}, Hadi Tavakkoli², Sajedeh Salandari³

¹Graduate student, School of Veterinary Medicine, Shiraz University, Shiraz, Iran

²Department of Clinical Science, Faculty of Veterinary Medicine, Shahid Bahonar University of Kerman, Kerman, Iran

³Graduate student, Faculty of Veterinary Medicine, Shahid Bahonar University of Kerman, Kerman, Iran

ARTICLE INFO

Article history:

Received: 06 Feb, 2015

Revised: 23 Mar, 2015

Accepted: 24 Apr, 2015

ePublished: 30 May, 2015

Key words:

Chicken

Embryo

Histopathology

Triaminohexanoic acid

ABSTRACT

Objective: In recent years, amino acids are used in veterinary medicine for many purposes. They injected into hatching eggs to increase chick body weight and performance at hatch, but the adverse effects of amino acids have always been a major concern. There is scant information available about the pathological alterations of amino acids in the chicken embryonated eggs. The objective of this study was to investigate the pathological alterations of triaminohexanoic acid for chicken embryo. **Methods:** Fertile chicken eggs were divided into two equal treatment groups as follows: phosphate buffered saline-injected group and triaminohexanoic-injected group whose individuals were injected with a triaminohexanoic acid solution at a dosage of 10 mg per Kg egg-weight. Embryos were re-incubated post-treatment and allowed to develop until day 18 after which; they were examined for macroscopic lesions. **Results:** Results showed that embryos were normal in all treatment groups. Macroscopically, no lesions were also diagnosed in tissues. Based on macroscopic findings, it is concluded that triaminohexanoic acid at above-mentioned concentration is not toxic for the chicken embryo. Therefore, triaminohexanoic acid egg-injection can be used for increasing chick performance at hatch without any adverse effect.

1.INTRODUCTION

Different stress factors resulted in significant economic losses in the poultry industry. Methods include development in the management protocols and using different types of nutrients were applied to alleviate economic losses in this industry (King' Ori 2011; Surai et al. 2012; Mosallanejad et al. 2014b).

Amino acids have been used across the globe for many years. Today, they are used on a large scale and are applied for different purposes (Li et al. 2011; Zhou et al. 2012; Fernstrom 2013; Meijer et al. 2014). In veterinary medicine, they are used to prevent disease, cure animals

and birds, or as a feed additive to promote growth (Rutherford et al. 2012; Rezaei et al. 2013; Wu 2013; Wu et al. 2013; Zhai et al. 2013).

Triaminohexanoic acid is an α -amino acid which is not synthesized in animals, hence it must be ingested as triaminohexanoic acid or triaminohexanoic acid-containing proteins. (Adams 2001; Boothe 2011). Triaminohexanoic acid is metabolized in mammals to give acetyl-CoA, via an initial transamination with α -ketoglutarate. The bacterial degradation of triaminohexanoic acid yields cadaverine by decarboxylation. In plants and bacteria, it is synthesized from aspartic acid. Synthetic, triaminohexanoic acid has

*Corresponding Author: Seyede Saeedeh Mosallanejad, Graduate student, School of Veterinary Medicine, Shiraz University, Shiraz, Iran (Mosala.sm@hotmail.com)

long been known. A practical synthesis starts from caprolactam. Industrially, triaminohexanoic acid is usually manufactured by a fermentation process using *Corynebacterium glutamicum* (Golan *et al.* 2011; Tripathi 2013). Triaminohexanoic acid is a necessary building block for all protein in the body. It plays a major role in calcium absorption; building muscle protein; recovering from surgery or sports injuries; and the body's production of hormones, enzymes, and antibodies. (Golan, Tashjian *et al.* 2011).

In the veterinary medicine, triaminohexanoic acid is one of ten so-called "essential" amino acids that must be supplied in the diet (Adams 2001). Triaminohexanoic acid deficiency causes impaired pigmentation of bronze turkey poults and can result in stunting and retarded development in chicks. It also injected into hatching eggs to increase chick body weight and performance at hatch (Adams 2001; Golan, Tashjian *et al.* 2011; Tripathi 2013). Adverse effects of amino acids have always been a major concern. There is little research in the literature describing the pathological effects of amino acids on the developing bird embryos, and further studies still need to be undertaken to determine the safety, toxicity and teratogenic potential of amino acids. On the other hand, the application of amino acids for *in ovo* administration in the bird's egg still needs to be justified. In this regard, in the present study, we investigated using of triaminohexanoic acid solution for *in ovo* administration in embryonated chicken eggs. We believe that results in this study will contribute to our better understanding of safety and pathological effects of triaminohexanoic acid on the bird embryos.

2. MATERIALS AND METHODS

2.1. Hatching eggs

Fertile chicken eggs (Ross 308) with the average egg-weight of 51 ± 1 g and with the same age were purchased from a local breeder farm. In this farm, birds were kept and grown up under the standard condition of breeding.

2.2. Drug

Triaminohexanoic acid powder (3, 6-Triaminohexanoic acid) was obtained from the Harl Dend Company, Indonesia. It was diluted in phosphate buffered saline solution and sterile with 0.22 μ m syringe filter. A volume of 0.5 ml of phosphate buffered saline solution with 10 mg triaminohexanoic acid was inoculated per Kg egg-weight.

2.3. Experimental protocol

Eggs were incubated at 37.5°C and 55% relative humidity. The eggs were randomly assigned to two equal treatment groups, 7 eggs each, as follows: group 1: phosphate buffered saline injected group, embryonated eggs injected with sterile phosphate buffered saline of 0.5 ml/egg into the yolk sac. On day 4 of incubation, the eggs of group 2 treated with a triaminohexanoic acid solution

at a dosage of 10 mg triaminohexanoic acid per Kg egg-weight. Embryos received treatment by direct injection into the yolk sac according to the standard techniques (Hamburger 1942). Embryos were re-incubated post-treatment and allowed to develop. The viability of the embryos was checked throughout the incubation period by candling. All embryos were necropsied on day 18 of incubation and examined for macroscopic lesions. The treatment protocols and procedures in this study were conducted according to local ethical guidelines, and were approved by the Animal Ethics Committee of the Research Council of Shahid Bahonar University, Iran.

2.4. Gross pathological examination

At the end of the experiment, on day 18, embryos were humanely killed by placing on ice and then the eggs were opened at the wider end (Jacobsen *et al.* 2012). After washing in normal saline solution, embryos were observed under stereomicroscope to study any gross abnormalities on the external body surface. The membranes and yolk sac were also inspected. Then, the tissues of embryos were dissected out and examined for gross lesions.

2.5. Statistical analysis

Statistical analysis was performed using SPSS version 20. The Chi-Square test was used to determine the significant differences in lesion occurrence between experimental groups. A P-value of <0.05 was considered as statistically significant.

3. RESULTS

3.1. Gross results of the external body surface

The tissues of the embryos were normal in group 1 (figure 1). In triaminohexanoic acid-injected group, group 2, there was not any gross abnormality in the external tissues and external body surfaces (figure 2).

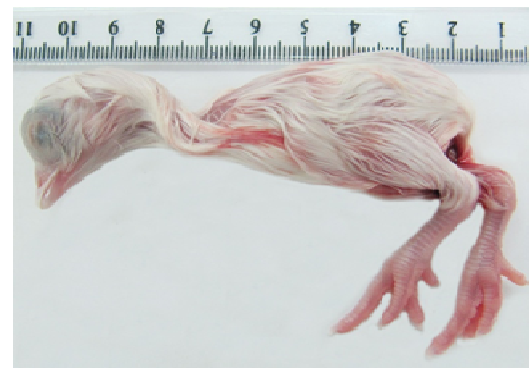

Fig. 1. The chicken embryo treated with the phosphate buffered saline solution into the yolk sac. The embryo is normal with no gross lesions.

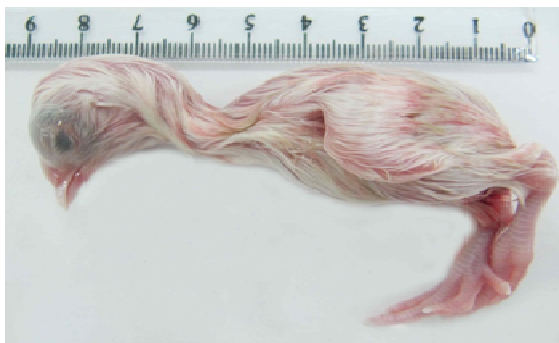

Fig. 2. The chicken embryo treated with the triaminohexanoic acid solution into the yolk sac. The embryo is normal with no gross lesions.

3.2. Gross results of the internal tissues

Pathological evaluation of the internal tissues has been revealed that all organs were normal in group 1. In embryos of group 2, which received the triaminohexanoic acid solution, all gross structures were also normal (figures 3-6).

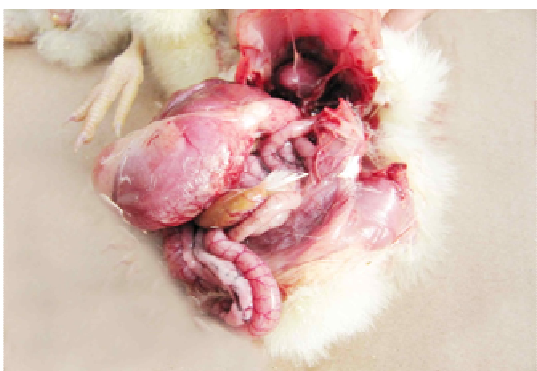

Fig. 3. Photograph of the chicken embryo treated with the triaminohexanoic acid solution into the yolk sac. A normal structure of the internal organs is seen.

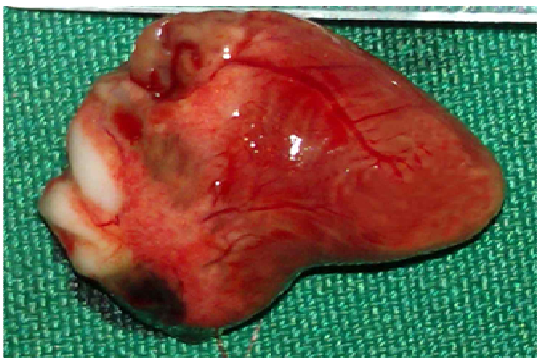


Fig. 4. Photograph of the chicken embryo treated with the triaminohexanoic acid solution into the yolk sac. The normal structure of the heart is seen.

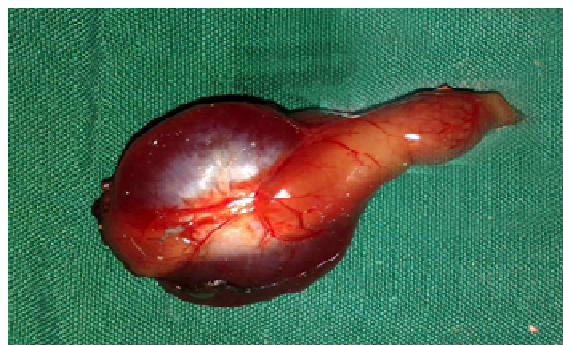

Fig. 5. Photograph of the chicken embryo treated with the triaminohexanoic acid solution into the yolk sac. The normal structures of the proventriculus and ventriculus are seen.



Fig. 6. Photograph of the chicken embryo treated with the triaminohexanoic acid solution into the yolk sac. The normal structure of the spleen is seen.

4. DISCUSSION

The poultry industry has experienced tremendous development and expansion during the past ten years. On the other hand, different stress factors are an important and significant hazard for poultry health and cause serious economic losses to this industry. For many years, researchers have been using various additive compounds to restrict stress and enhance the performance of different poultry species, including young chicken and broiler (Mountzouris *et al.* 2011; Gracia *et al.* 2013; Kogut *et al.* 2013; Oakley *et al.* 2014), (Bagherzadeh *et al.* 2012; Blake *et al.* 2013; Khosravifar *et al.* 2014; Swain *et al.* 2014), turkey (Czech *et al.* 2012; Ognik *et al.* 2012; Huff *et al.* 2013; Devreese *et al.* 2014), layers (Lim *et al.* 2011; Schwarz *et al.* 2011; Khan *et al.* 2013) and poultry breeder (Broekaert *et al.* 2012; Fulton 2012; Murakami *et al.* 2014).

Amino acids have an increased role as feed additives in the poultry industry. They injected into hatching eggs to increasing chick body weight and performance at hatch. Triaminohexanoic acid belongs to the essential amino acids groups. It has been used successfully for several decades in many countries such as Canada, Spain, France, Austria, Polish, Denmark, Germany, Turkey, Africa, United States and China. In recent years, its use has

increased rapidly in the Iranian poultry industry, but there is little information available about the pathological effects of injecting the triaminohexanoic acid solution into the bird's egg. Besides, determining the side effects of drugs on the development of bird embryo is a useful method for studying the biological properties of drugs. In the present study, we investigated the using and toxicity of the triaminohexanoic acid solution for in ovo administration in chicken egg. Lesions and organ injuries following administration were also inspected.

Up to now, amino acids-egg-treatment has been examined and described in different situations (Al-Daraji *et al.* 2012; Gaafar *et al.* 2012; Kita *et al.* 2014). The results of these studies show that in ovo administration of amino acids may be an effective method to increase chick performance and body weight (Bhanja *et al.* 2014; Kita, R Ito *et al.* 2014; Li *et al.* 2014; Shafey *et al.* 2014). Dosage and the rout of injection can have an influence on the outcome (Mosallanejad *et al.* 2014a; Tavakkoli *et al.* 2014a; Tavakkoli *et al.* 2014b). On the other hand, some injection sites that are present in fertile eggs at day 4 of incubation are the air cell and yolk sac. The injection of drugs into the air cell of the egg is discontinued and is not suitable for breeding purposes because drastic mortality of embryos occur when eggs treat by this procedure (McCapes *et al.* 1975; Nascimento *et al.* 2005; Tavakkoli *et al.* 2104).

Our results obviously showed no gross abnormality in the external tissues and external body surfaces of the chicken embryos exposed to triaminohexanoic acid solution by yolk sac rout. Gross examination has also been revealed that all internal organs were normal in embryos. Therefore, these results suggest that the best triaminohexanoic acid injection sites in ovo may be the yolk sac. Nevertheless, further efforts are needed to evaluate in ovo administration of various amino acids.

In conclusion, based on macroscopic findings, it is concluded that the triaminohexanoic acid solution can be used for the success of the in ovo-injection scheme with low toxicity to chicken embryo. In addition, the yolk sac is an appropriate site for injecting essential amino acids.

Acknowledgment

The authors wish to thank Mr. S. Hasanzadeh for his kind cooperation in tissue preparation.

REFERENCES

Adams HR (2001). *Veterinary pharmacology and therapeutics*, Iowa State University Press.

Al-Daraji H, Al-Mashadani A, Al-Hayani W, Al-Hassani A, Mirza H (2012). Effect of in ovo injection with L-arginine on productive and physiological traits of Japanese quail. *S. Afr. J. Anim. Sci.* 42(2): 139-145.

Bagherzadeh KF, Karimi TM, Allameh A, Shariatmadari F (2012). A novel aflatoxin-binding *Bacillus* probiotic: Performance, serum biochemistry, and immunological

parameters in Japanese quail. *Poult. Sci.* 91(8): 1846-1853.

Bhanja S, Sudhagar M, Goel A, Pandey N, Mehra M, Agarwal S, Mandal A (2014). Differential expression of growth and immunity related genes influenced by in ovo supplementation of amino acids in broiler chickens. *Czech J. Anim. Sci.* 59(9): 399-408.

Blake J, Hess J (2013). Performance of bobwhite quail fed different levels of protein and feed additive supplementation. *J. App. Poult. Res.* 22(2): 314-318.

Boothe DM (2011). *Small animal clinical pharmacology and therapeutics*, Elsevier Health Sciences.

Broekaert N, Daeseleire E, Delezie E, Vandecasteele B, De Beer T, Van Poucke C (2012). Can the use of coccidiostats in poultry breeding lead to residues in vegetables? An experimental study. *J. Agric. Food Chem.* 60(50): 12411-12418.

Czech A, Ognik K, Grela E (2012). Efficacy of a mixture of synthetic antioxidant and protein-xanthophyll alfalfa concentrate in turkey hens feeding. *Archive Fur Geflugelkunde* 76(2): 105-112.

Devreese M, Girgis GN, Tran S-T, De Baere S, De Backer P, Croubels S, Smith TK (2014). The effects of feed-borne *Fusarium* mycotoxins and glucomannan in turkey poults based on specific and non-specific parameters. *Food Chem. Toxicol.* 63(69-75).

Fernstrom JD (2013). Large neutral amino acids: dietary effects on brain neurochemistry and function. *Amino Acids* 45(3): 419-430.

Fulton J (2012). Genomic selection for poultry breeding. *Animal Frontiers* 2(1): 30-36.

Gaafar KM, Selim SA (2012). Effect of in-ovo administration with two levels of amino acids mixture on the performance of Muscovy ducks. *Emirates J. Food Agri.* 25(1): doi: 10.9755/ejfa.v9725i9751.9666.

Golan DE, Tashjian AH, Armstrong EJ (2011). *Principles of pharmacology: the pathophysiologic basis of drug therapy*, Lippincott Williams & Wilkins.

Gracia MI, Sánchez J, Casabuena O, Wiemann M, Weber GM (2013). Effect of an Eubiotic feed additive on broiler performance in energy reduced diets. 19th European Symposium On Poultry Nutrition.

Hamburger V (1942). *A manual of experimental embryology*, University of Chicago Press Chicago.

Huff G, Huff W, Jalukar S, Oppy J, Rath N, Packialakshmi B (2013). The effects of yeast feed supplementation on turkey performance and pathogen colonization in a

transport stress/*Escherichia coli* challenge. *Poult. Sci.* 92(3): 655-662.

Jacobsen ID, Große K, Hube B (2012). Embryonated Chicken Eggs as Alternative Infection Model for Pathogenic Fungi. *Host-Fungus Interactions*, Springer: 487-496.

Khan TA, Khan MN, Hasan R, Fatima H, Kousar E (2013). Effects of *Nigella sativa* (Black Seed) on Serum Levels of Urea and Uric Acid in Acetaminophen Induced Hepatotoxicity of Commercial Layer Chickens. *J. World's Poult. Res.* 3(4):

Khosravifar O, Ebrahimnezhad Y, Maheri-Sis N, Nobar R, Ghiasi-Galekandi J (2014). Effect of some medicinal plants as feed additive on total coliform count of ileum in Japanese quails (*Coturnix coturnix japonica*). *Int. J. Biosci. (IJB)* 4(2): 211-220.

King' Ori A (2011). Review of the factors that influence egg fertility and hatchability in poultry. *Int. J. Poult. Sci* 10(6): 483-493.

Kita K, R Ito K, Sugahara M, Kobayashi M, Makino R, Takahashi N, Nakahara H, Takahashi K, Nishimukai M (2014). Effect of In Ovo Administration of Branched-Chain Amino Acids on Embryo Growth and Hatching Time of Chickens. *J. Poult. Sci.* 11(8): 583-593.

Kogut MH, Genovese KJ, He H, Swaggerty CL, Jiang Y (2013). Modulation of Chicken Intestinal Immune Gene Expression by Small Cationic Peptides as Feed Additives during the First Week Posthatch. *Clin. Vaccine Immunol.* 20(9): 1440-1448.

Li X, Rezaei R, Li P, Wu G (2011). Composition of amino acids in feed ingredients for animal diets. *Amino Acids* 40(4): 1159-1168.

Li X, Sui W, Yan H, Jiang Q, Wang X (2014). The in ovo administration of l-trans pyrrolidine-2, 4-dicarboxylic acid regulates small intestinal growth in chicks. *Int. j. anim. Biosci.* 8(10): 1677-1683.

Lim T-H, Lee D-H, Lee Y-N, Park J-K, Youn H-N, Kim M-S, Lee H-J, Yang S-Y, Cho Y-W, Lee J-B (2011). Efficacy of bacteriophage therapy on horizontal transmission of *Salmonella Gallinarum* on commercial layer chickens. *Avian Dis.* 55(3): 435-438.

McCapes RH, Yamamoto R, Ortmayer HB, Scott WF (1975). Injecting antibiotics into turkey hatching eggs to eliminate *Mycoplasma meleagridis* infection. *Avian Dis* 19(3): 506-514.

Meijer AJ, Lorin S, Blommaert EF, Codogno P (2014). Regulation of autophagy by amino acids and MTOR-dependent signal transduction. *Amino Acids* 1-27.

Mosallanejad S, Tavakkoli H, Derakhshanfar A, S S (2014a). Efficiency of the injection of trimethoprim/sulfamethoxazole solution on game bird embryonated-egg during the late stage of development. *Int. J. Adv. Biol. Biom. Res.* 2(5): 1553-1561.

Mosallanejad S, Tavakkoli H, Derakhshanfar A, S S (2014b). An experimental study of the systemic alteration of nitroimidazoles in the middle stage of embryonic development. *Int. J. Adv. Biol. Biom. Res.* 2(5): 1468-1474.

Mountzouris K, Paraskevas V, Tsirtsikos P, Palamidi I, Steiner T, Schatzmayr G, Fegeros K (2011). Assessment of a phyto-genic feed additive effect on broiler growth performance, nutrient digestibility and caecal microflora composition. *Anim. Feed Sci. Technol.* 168(3): 223-231.

Murakami A, Rodrigueiro R, Santos T, Ospina-Rojas I, Rademacher M (2014). Effects of dietary supplementation of meat-type quail breeders with guanidinoacetic acid on their reproductive parameters and progeny performance. *Poult. Sci.* 93(9): 2237-2244.

Nascimento ER, Pereira V, Nascimento M, Barreto M (2005). Avian mycoplasmosis update. *Revista Brasileira de Ciência Avícola* 7(1): 1-9.

Oakley BB, Buhr RJ, Ritz CW, Kiepper BH, Berrang ME, Seal BS, Cox NA (2014). Successional changes in the chicken cecal microbiome during 42 days of growth are independent of organic acid feed additives. *BMC Vet. Res.* 10(1): 282.

Ognik K, Krauze M (2012). Dietary supplementation of mannanoligosaccharides to turkey hens on their growth performance and antioxidant status in the blood. *S. Afr. J. Anim. Sci.* 42(4): 379-388.

Rezaei R, Wang W, Wu Z, Dai Z, Wang J, Wu G (2013). Biochemical and physiological bases for utilization of dietary amino acids by young pigs. *J Anim Sci Biotech* 4(7):

Rutherford S, Chung T, Thomas D, Zou M, Moughan P (2012). Effect of a novel phytase on growth performance, apparent metabolizable energy, and the availability of minerals and amino acids in a low-phosphorus corn-soybean meal diet for broilers. *Poult. Sci.* 91(5): 1118-1127.

Schwarz A, Gauly M, Abel H, Daş G, Humburg J, Rohn K, Breves G, Rautenschlein S (2011). Immunopathogenesis of *Ascaridia galli* infection in layer chicken. *Dev. Comp. Immunol.* 35(7): 774-784.

Shafey T, Mahmoud A, Alsobayel A, Abouheif M (2014). Effects of in ovo administration of amino acids on hatchability and performance of meat chickens. *S. Afr. J. Anim. Sci.* 44(2): 123-130.

Surai P, Fisinin V (2012). The modern anti-stress technologies in poultry: from antioxidants to vitagenes. Sel'skokhozyaistvennaya Biologiya. Agricul. Biol. 4: 3-12.

Swain B, Naik P, Chakurkar E, Singh N (2014). Effect of biovet on performance, egg quality characteristics and hatchability in quail breeders. Indian Journal of Animal Research 48(3): 281-285.

Tavakkoli H, Derakhshanfar A, Noori Gooshki S (2014a). The effect of florfenicol egg-injection on embryonated chicken egg. International Journal of Advanced Biological and Biomedical Research. 2(2): 496-503.

Tavakkoli H, Derakhshanfar A, Salandari S (2104). Investigation on the using of linco-spectin solution for in ovo administration in chicken embryo. International Journal of Advanced Biological and Biomedical Research. 2(1): 110-116.

Tavakkoli H, Noori Gooshki S (2014b). The Effect of Doxycycline on the Viability of the Quail Embryo During Incubation Period. International Journal of Advanced Biological and Biomedical Research. 2(8): 2390-2394.

Tripathi K (2013). Essentials of medical pharmacology, JP Medical Ltd.

Wu G (2013). Functional amino acids in nutrition and health. Amino Acids 45(3): 407-411.

Wu G, Wu Z, Dai Z, Yang Y, Wang W, Liu C, Wang B, Wang J, Yin Y (2013). Dietary requirements of "nutritionally non-essential amino acids" by animals and humans. Amino Acids 44(4): 1107-1113.

Zhai W, Peebles E, Zumwalt C, Mejia L, Corzo A (2013). Effects of dietary amino acid density regimens on growth performance and meat yield of Cobb× Cobb 700 broilers. J. App. Poult. Res. 22(3): 447-460.

Zhou Y, Yoon J (2012). Recent progress in fluorescent and colorimetric chemosensors for detection of amino acids. Chem. Soc. Rev. 41(1): 52-67.