



Study on Parasitic infections of Quails in Garmsar, Iran

Shemshadi Bahar, Ranjbar Bahadori Shahrokh, Mirakhori Mohsen

Parasitology Department, Veterinary Faculty, Islamic Azad University, Garmsar branch

ABSTRACT

In this study parasitic infection of bobwhite and Japanese quails were clarified in farms of Garmsar city in province of Semnan. Forty quails from two breeds randomly were selected and they examined to identify all internal and external parasites. Finding was shown that five percent of the quails examined harbored one or more species of helminthes. Two cestodes, Raillietina echinobothrida and Raillietina cysticillus were found in small intestine. One of female bobwhite quails was infected by R.echinobothrida and one male bobwhite quails was infected by R.cysticillus. Eight of forty quails harbored intestinal Cryptosporidiosis (20%) and thirteen of forty quails had tracheal cryptosporidiosis (32.5%). Intestinal cryptosporidiosis was clarified in three male and one female of both bobwhite and Japanese quails and tracheal cryptosporidiosis was found in four male and five female of bob white quails and three male and one female of Japanese quails. Also in this study significant difference was determined between female Bob white breed & female Japanese breed in case of tracheal cryptosporidiosis ($p < 0.05$). In this study, there was no ectoparasite on quails.

Key words: Parasitic infection, Quail, Garmsar

INTRODUCTION

Quails are mid-sized birds generally considered in the order Galliformes. There are two important species, The Japanese quails (*Coturnix Japonica*) and Bobwhites quails (*Colinus virginianus*). The Japanese quail originates from Eastern Asia and Bobwhites are from United-State. Their domestication has begun in the fourteen century. In recent years, in many parts of Iran, quail farms have been established. These birds have recognized as very useful and economic birds because of their meats and eggs. Quails meat is white and it has high qualification. In the present study parasitic infections of quails were examined in Garmsar to identify blood parasites, intestinal protozoans, Intestinal helminthes and ectoparasite.

MATERIALS AND MTHODES

In this study 20 Japanese and 20 bobwhite quails were collected randomly from quail farms of Garmsar. After arrival at the laboratory, live birds were killed by decapitation. Blood films were made immediately, and stained with Giemsa stain. The birds were then necropsies and the large

and small intestine opened. Slide smears for protozoan parasites were made from rectal and cecal samples obtained with sterile cotton swabs. These smears were fixed in Schaudin's fixative and stained with trichrome stain. Also the modified acid-fast staining technique was used to identify *Cryptosporidium*, the oocysts appear as pink to red, spherical to ovoid, bodies on a blue or purple background. The entire intestinal tracts were opened and helminthes parasites were individually recovered, fixed and stored for later identification. Ectoparasites were collected from surface body of quails and specimens were identified with direct macroscopic and microscopic examination.

RESULTS

Helminthes Infections

Five percent of the quails examined harbored one or more species of helminthes. Two cestodes, *Raillietina echinobothrida* and *Raillietina cysticillus* were found in small intestine. One of female bobwhite quails was infected by *R.echinobothrida* and one male bobwhite quails was infected by *R.cysticyllus* (Table1, 2)

Protozoan Infections

Eight of forty quails harbored intestinal *Cryptosporidiosis* (20%) and thirteen of forty quails had tracheal *cryptosporidiosis* (32.5%). According to the table number 2 intestinal *cryptosporidiosis* was clarified in three male and one female of both bobwhite and Japanese quails and tracheal *cryptosporidiosis* was found in four male and five female of bob white quails and three male and one female of Japanese quails. Also in this study significant difference was determined between female Bob white breed & female Japanese breed in case of tracheal *cryptosporidiosis* ($p < 0.05$).

Ectoparasite:

In this study, there was no ectoparasite on quails.

Table 1- Prevalence of parasitic infections in quails in Garmsar.

Parasite identified	frequency	Percent of infection
<i>Cryptosporidium</i> in tracheal	13	32.5%
<i>Cryptosporidium</i> in intestinal	8	20%
<i>Raillietina echinobothrid</i>	1	2.5%
<i>Raillietina cysticylus</i>	1	2.5%

Table 2- Prevalence of parasitic infections in Bobwhite and Japanese quails.

Quail	Bobwhite	Japanese
-------	----------	----------

	Male	Female	male	female	total
Parasite identified					
Cryptosporidium in tracheal	4	5	3	1	13
Cryptosporidium in intestinal	3	1	3	1	8
Raillietina echinobothrida	0	1	0	0	1
Raillietina cysticylus	1	0	0	0	1

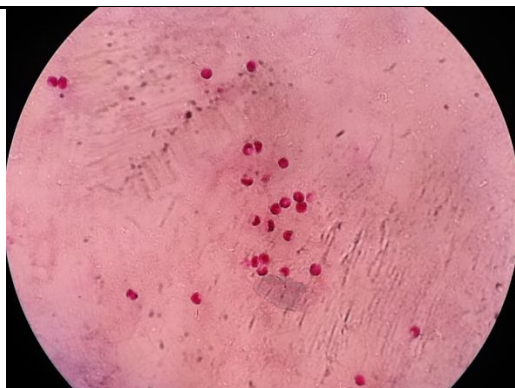


Figure 1: Cryptosporidium smears with modified Zeilnelson

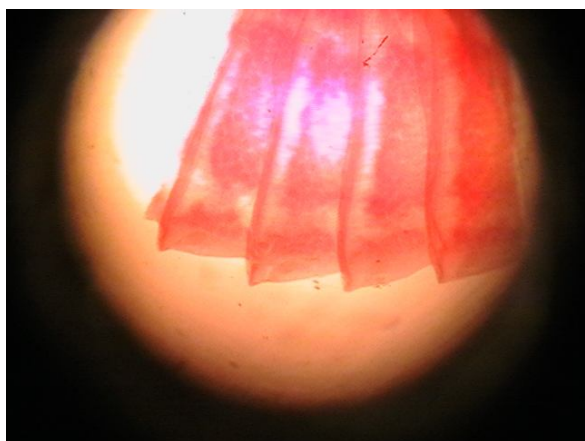


Figure 2: Raillietina echinobothrida in intestine of quails was smeared with Acetocarmen dye

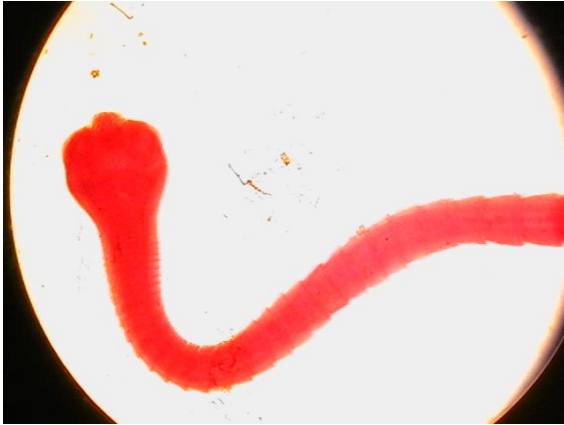

Figure 3: Raillietina Cysticylus in intestine of quails was smeared with Acetocarmen

DISCUSSION

In recent years the quail has become very important in economy of some areas of Iran for commercial meat sale. Also there is not useful information about parasitic infections of quails in Iran. In this study for the first time in Iran some protozoan parasites such as *Cryptosporidium* were determined in examined quails in Garmsar and *Raillietina echinobothrida* and *R.cysticyllus* two species of cestods that were found in quails. Parasitic infection cause loss of weight in birds and it is important in economic aspect. It is suggested that hot weather in summer in this area must be produced limited parasitic infection in quails of Garmsar especially in warm seasons of the year. According to this study there was significant difference between female Bob white breed & female Japanese breed in case of tracheal cryptosporidiosis. It means breed can influence on infestation. In the other hand *cryptosporidium* is known to be capable of producing disease in quail and other wild and domestic birds.

In similar study in 1989 the intestines of 150 grey quails (*Coturnix coturnix*) were examined at postmortem, for tapeworm's infestation. Two species of cestodes were collected *Raillietina echinobothrida* and *Choanotaenia infundibulum*. The prevalence, average number of worms per bird and their morphology were reported. Its worth to mention that quail was found to be a new host for *R. echinobothrida* by Otify (1989).

In the other study bobwhite quail from Oklahoma was studied over a 1-year period. The nematodes *Subularia brumpti* and *Heterakis gallinarum* were recovered from 27% and 4% of the birds examined respectively. Unidentified cestodes were recovered from 6% of the birds examined. Four genera and five species of protozoa were identified; *Trichomonas* sp. (45%), *Chilomastix* sp. (30%), *Eimeria* sp. (27%), *Trichomonas gallinarum* (25%), and *Histomonas meleagridis* (7%). (Alan kocan et al. 1979)

In 2011 in Saudi Arabia study was aimed to clarify the difference of the intensity of parasitic infection between the domestic quails *Coturnis coturnis* and the migrant ones. A total of 60 domesticated and 60 migratory quails were investigated during the migration season September-November 2009 for intestinal parasites. Investigations revealed that both domestic and migrant quails were susceptible to infection with three helminth parasites; a nematode (*Heterakis gallinarum*), and two cestodes (*Choanotaenia infundibulum* and *Hymenolepis* sp.). The prevalence of infection in the migratory males was higher than the female ones, the opposite results was

obtained for the domestic birds. The differences in the prevalence were found to be statistically significant in case of the domestic birds. Single infection showed the highest prevalence followed by the double infection and finally the triple infection. The mean intensity of infection in the female domestic and migrant *C. coturnix* was higher than male. (Mohamed et al. 2011). According to the issue parasitic infection in quails are very important and it is useful to do spread investigation to identify and control of parasitic infection in quails and other domestic and wild birds in the country.

REFERENCES

Alan Kocan, A., Hannon, L., Hammond Eve, J., (1979). SOME PARASITIC AND INFECTIOUS DISEASES OF BOBWHITE QUAIL FROM OKLAHOMA ., *Oclahoma Academy Science*. 59: 20-22 (1979)

Bodily, H., Updyke, E., Mason, J. (1970). Diagnostic procedures for bacterial, mycotic and parasitic infections .*American Public Health Association*,

Melhorn, H., Bunang, D., (1988). *Parasitology in focus*.

Mohamed SH, Ghobashy MA, Al-Zailae HA., (2011). Levels of helminthic infections in the quails *Coturnix coturnix* from Kingdom of Saudi Arabia. *Journal Egypt Society Parasitology*. Aug; 41(2): 397-407

Otify, YZ., (1989). Tapeworms of quails (*Coturnix coturnix*) in Egypt. *Journal Egypt Society Parasitology*. Jun; 19 (1): 81-4.