

Microscopic Study of Histological Changes the Use of Ileal Mucosa as a Bladder (Radical Cystectomy - Case Report)

Sareh Najaf Asaadi, Hassan Morovvati, Ahmad Reza Taftachi



CrossMark
click for updates

DOI: 10.18869/IJABBR.2018.125

International Journal of Advanced Biological and Biomedical Research

Journal DOI: 10.18869/IJABBR

ISSN: 2322-4827

CODEN (USA): IJABIS

<http://ijabbr.com>



Copyright © 2018 by authors and CASRP Publishing Company, Ltd, UK. This work is licensed under the Creative Commons Attribution International License (CC BY4.0).

<https://creativecommons.org/licenses/by/4.0/>



Available online at <http://ijabbr.com>

CASRP PUBLISHER

International Journal of Advanced Biological and Biomedical Research 7(1) (2018) 125–128

doi: 10.18869/IJABBR.2018.125



Case Report

Open Access

Microscopic Study of Histological Changes the Use of Ileal Mucosa as a Bladder (Radical Cystectomy - Case Report)

Sareh Najaf Asaadi^{1,*}, Hassan Morovvati², Ahmad Reza Taftachi³

¹Ph.D. Student of Histology, Faculty of Veterinary Medicine, University of Tehran, Tehran, Iran.

²Department of Basic Science, Faculty of Veterinary Medicine, University of Tehran, Tehran, Iran.

³Urologist, FEBU at Sapir Hospital, Tehran, Iran.

Abstract

Cancer can significantly have ruining effects on very high of human beings, social, and economic condition. Bladder cancer has been reported as one of the most common cancers and the incidence rates of this cancer is increasing across the world. Cystectomy is a surgery to remove the urinary bladder. In the present study a part of the ileum is used instead of bladder. This study deals with mucosa morphological changes induced in a patient with history of cystectomy surgery, an 8-year follow-up. The specimens were stained with hematoxylin-eosin in order to examine the changes in the thickness of the mucosa processed for light and electronic microscopy. During examining microscopic slides simple epithelial tissue with goblet cells were observed. Also, Lieberkuhn gland and loose connective tissue were seen. The existence of thick layers at cylindrical cells, it could be due to urinating. Finally, goblet cells maybe loss the property of mucosa secretion.

© 2018 Published by CASRP Publishing Company Ltd. UK. Selection and/or peer-review under responsibility of Center of Advanced Scientific Research and Publications Ltd. UK.

Keywords: Ileum mucosa, Bladder, Cystectomy

1. Introduction

The health science has faced with major challenges for management of bladder disorder, and common therapeutic methods often results in unsatisfactory results. However, in the last 15 years, efforts have been made

*Corresponding author: najaf.asaadi@ut.ac.ir

© 2018 The Authors. This is an open access article under the terms of the Creative Commons Attribution-Non Commercial- No Derives License, which permits use and distribution in any medium, provided the original work is properly cited, the use is non-commercial and no modifications or adaptations are made.

Received 19 January 2018

iThenticate screening 22 January 2018

Accepted 20 May 2018

English editing 18 May 2018

Available online 30 May 2018

Quality control 28 May 2018

to preserve patient body image and quality of life by constructing continent bladder substitutes (Benson et al., 1996). Nowadays, replacement of a part of the ileum instead of bladder universally recognized as cost-effective, being the most clinically adequate, and reliable solution in the long term.

Types of bladder disease have a great impact on different aspects of quality of life. Bladder cancer is the second most common cancer of the genito-urinary tract (Sherwani Afak et al., 2009). There is a wide disparity in practice in the selection of method for urinary diversion worldwide (Gore et al., 2006; Gore and Litwin, 2009). Traditionally, the gold standard care for muscle-invasive bladder cancer in men is cystectomy, cystectomy is a surgery to remove the urinary bladder, with urinary reconstruction. At radical cystectomy almost each segment of gastrointestinal tract has been used to create urinary reservoirs or conduits. The cystectomy is one of the simplest, oldest, the acceptable complication rate, and most commonly performed techniques. Although much of the clinical evidence coming from radical cystectomy is of low quality, major international guideline strongly recommended radical cystectomy as the elective treatment for muscle-invasive bladder cancer (Stenzl et al., 2009).

To our knowledge, no previous studies have addressed the use of ileum as a bladder in patients with history of cystectomy surgery, an 8-year follow-up in Iranian population, so we performed this comparison.

2. Materials and methods

2.1. Preoperative counseling and preparation

Before proceeding to surgery, a detailed explanation of the aims and potential complications of cystectomy and the advantages and disadvantages of each urinary diversion method were provided for the patient.

2.2. Case study

The man (80 y old) had muscle invasive carcinoma urinary bladder and was treated with standard radical cystectomy surgery in males, an 8-year follow-up. The specimens were stained with hematoxylin-eosin in order to examine the changes in the thickness of the mucosa processed for light and electronic microscopy (Olympus, Tokyo, Japan, BX60). Samples for light microscopy were fixed 10% buffered formalin and embedded in paraffin; 5-7 μ m thick sections were stained with hematoxylin and eosin (H & E) and periodic-acid Schiff stain. Samples for transmission electron microscopy were fixed in cacodylate-buffered glutaraldehyde, post-fixed in osmium tetroxide and embedded in Epon resin.

3. Results and discussion

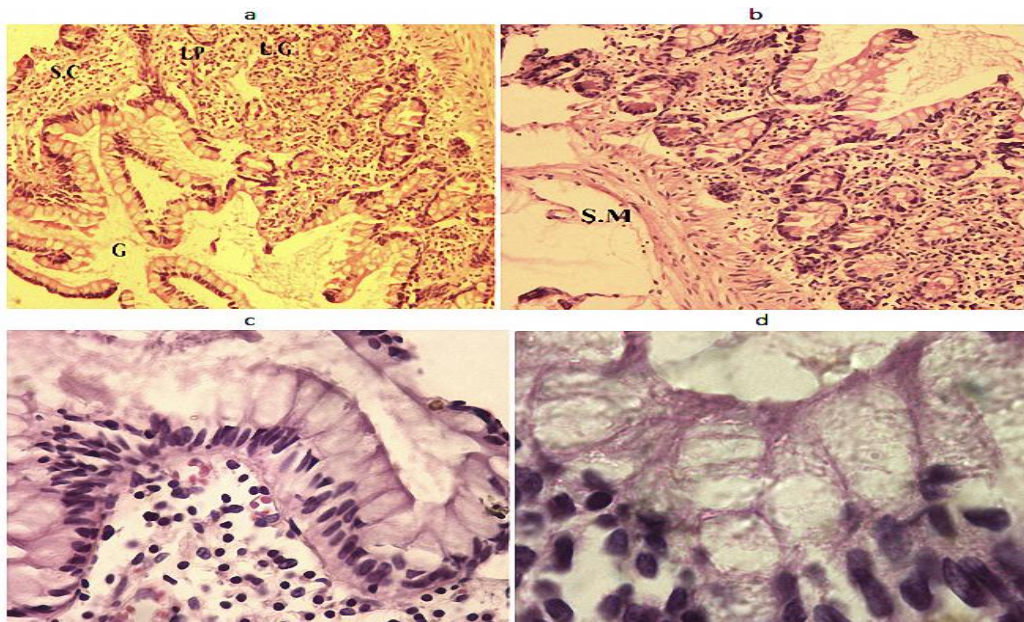


Fig. 1. Light microscopy of ileal mucosa.

Fig. 1a shows areas with superficial cells with short and normal microvilli were visible. The amplification in the number and height villi was increasingly evident (Fig. 1b). There were a slight presence of goblet cells in epithelial tissue and an increase in the density of goblet cells (Fig. 1c). Finally Lieberkuhn gland and loose connective tissue were seen in Fig. 1d. S.C: Simple cuboidal epithelium; G: Goblet cells; LP: Connective tissue parin; LG: Lieberkuhn gland; SM: Soft muscle.

The main aim of the present study creating a bladder from ileal mucosa of small intestine, with preservation of the urethral sphincter mechanism at cystectomy. Based on our knowledge, the creating a bladder from ileal mucosa of small intestine is an appropriate method of cystectomy because of its simplicity and good satisfaction in the quality of life, without altering their appearance. Sherwani Afak et al. (2009) concluded that there were inherited advantages and disadvantages to each form of urinary diversion and the patient selection is important to identify the most appropriate method of diversion for an individual.

Aragona et al. (1998) in periodic endoscopy with biopsy of the ileal mucosa was performed in 90 patients 3-84 months after radical cystectomy and urinary diversion via an orthotopic neobladder, reported that late changes in the ileal neobladder mucosa appear to be an expression of a functional adaptation of the mucosa to the new environment. In confirmation of these findings, Asgari et al. (2013) has shown that histological modifications may alters the functional characteristics of the mucosa, particularly in absorption, or they may cause new pathology (i.e. malignancies) secondary to the modifications. These above finding, in line with the results present experiment.

Following cystectomy, slightly decreased the microvilli number (corresponding to the primitive surface epithelium). Aragona et al. (1998) suggested that reduction in microvilli might be attributable to the selection of modified cellular clones, or to a direct toxic effect of urine on the intestinal epithelium, or may result from disuse caused by lack of contact with the normal intestinal content. In overall, we believe that the new mucosa in bladder may be shows only a slight shortening of the microvilli and a good-preserved surface bladder epithelium.

In conclusion, the existence of thick layers at cylindrical cells, it could be due to urinating. Finally, goblet cells (corresponding to the primitive surface epithelium) maybe loss the property of mucosa secretion.

Acknowledgements

Supported by the Department of Basic Science, Faculty of Veterinary Medicine, University of Tehran, Tehran-Iran, Research Mentorship Program (Prof. Dr. H. Morovvati) of Higher Education Thesis Program. The authors acknowledge the Department of Basic Science, Faculty of Veterinary Medicine, University of Tehran, Tehran-Iran, for assistance.

Declaration of conflict of interests

The authors report that they have no other financial or personal relationships that could inappropriately influence or bias the content of the paper.

References

- Aragona, F., De Caro, R., Parenti, A., Artibani, W., Bassi, P., Munari, P.F., Pagano, F., 1998. Structural and ultrastructural changes in ileal neobladder mucosa: a 7-year follow-up. *Br. J. Urol.*, 81(1), 55-61.
- Asgari, M.A., Safarinejad, M.R., Shakhssalim, N., Soleimani, M., Shahabi, A., Amini, E., 2013. Quality of life after radical cystectomy for bladder cancer in men with an ileal conduit or continent urinary diversion: A comparative study. *Urol. Ann.*, 5(3), 190-196, doi: 10.4103/0974-7796.115747
- Benson, M.C., Seaman, E.K., Olsson, C.A., 1996. The ileal neobladder is associated with a high success and low complication rate. *J. Urol.*, 155, 1585-1588.
- Gore, J.L., Litwin, M.S., 2009. The urologic diseases in America project. Quality of care in bladder cancer: Trends in urinary diversion following radical cystectomy. *World J. Urol.*, 27, 45-50.
- Gore, J.L., Saigal, C.S., Hanley, J.M., Schonlau, M., Litwin, M.S., 2006. Urologic diseases in America project. Variations in reconstruction after radical cystectomy. *Canc.*, 107, 729-37.

- Sherwani Afak, Y., Wazir, B.S., Arif Hamid, Wani, M.S., Rafia Aziz, 2009. Comparative study of various forms of urinary diversion after radical cystectomy in muscle invasive carcinoma urinary bladder. *Int. J. Health Sci. (Qassim)*, 3(1), 3-11.
- Stenzl, A., Cowan, N.C., De Santis, M., Jakse, G., Kuczyk, M.A., Merseburger, A.S., Ribal, M.J., Sherif, A., Witjes, J.A., 2009. The updated EAU guidelines on muscle-invasive and metastatic bladder cancer. *Eur. Urol.*, 55(4), 815-825.

How to cite this article: Najaf Asaadi, S., Morovvati, H., Taftachi, A.R., 2018. Microscopic Study of Histological Changes the Use of Ileal Mucosa as a Bladder (Radical Cystectomy - Case Report). *International Journal of Advanced Biological and Biomedical Research*, 7(1), 125-128.

Submit your next manuscript to CASRP Central and take full advantage of:

- Convenient online submission
- Thorough peer review
- No space constraints or color figure charges
- Immediate publication on acceptance
- Inclusion in Google Scholar
- Research which is freely available for redistribution

Submit your manuscript at
<http://ijabbr.com>

