



## The effect of florfenicol egg-injection on embryonated chicken egg

Hadi Tavakkoli<sup>1\*</sup>, Amin Derakhshanfar<sup>2</sup>, Samaneh Noori Gooshki<sup>3</sup>

<sup>1\*</sup>Department of Avian Medicine, School of Veterinary Medicine, Shahid Bahonar University of Kerman, Kerman, Iran

<sup>2</sup>Center of comparative&experimental medicine, Basic sciences in infection diseases research center, School of medicine, Shiraz University of Medical Sciences, Shiraz, Iran

<sup>3</sup> School of Veterinary Medicine, Shahid Bahonar University of Kerman, Kerman, Iran

### Abstract

Pathogens are an important and significant hazard for human and animal health. In recent years, antibiotics are used to treat different types of infection caused by bacterial agents. In veterinary medicine, antibiotics injected into hatching eggs to eliminate pathogens and prevention of egg transmission of disease, but the adverse effects of drugs have always been a major concern. There is scanty information available about the safety and pathological alterations of florfenicol drug in embryonated eggs. The objective of this study was to investigate using of various dosages of florfenicol solution for in ovo administration in chicken embryo. Fertile chicken eggs were divided into four equal treatment groups as follows: group 1: no injected group. Group 2: phosphate buffered saline-injected group; whose individuals were injected with phosphate buffered saline. Groups 3 and 4 whose individuals were injected with florfenicol injectable solution at a dosage of 20 and 30 mg per Kg egg-weight, respectively. Embryos were re-incubated post-treatment and allowed to develop until day 18 after which; they were examined for macroscopic and microscopic lesions. Results showed that embryos were normal in all treatment groups. Microscopically, no lesions were also diagnosed in tissues. Based on macroscopic and microscopic findings, it is concluded that florfenicol at above-mentioned concentration is not toxic for the chicken embryo. So, florfenicol egg-injection can be used to eliminate pathogens and prevention of egg transmission of the disease without any adverse effect.

**Key words:** Chicken, Egg, Embryo, Florfenicol, Histopathology

### Introduction

In recent years, the poultry industry has a leading role among agricultural industries in many parts of the world. On the other hand, bacterial diseases resulted in significant economic losses in this industry. Fortunately, efforts to alleviate economic losses in poultry production due to bacterial diseases have been relatively successful. Methods include development in the management protocols and using different types of antibiotics (Swayne et al. 2013). Antibiotics have been used across the globe for many years. Today, they are used on a large scale and are applied for different purposes (Gharaibeh and Al-Rashdan 2011; Garner et al. 2013; Tavakkoli et al. 2014). In veterinary medicine, they are used to prevent disease, cure animals and birds, or as a feed additive to promote growth. Florfenicol is a broad-spectrums

synthetic antibacterial agent that is effective against most gram-positive and gram-negative bacteria isolated from domestic poultry and animals. It belongs to amphenicol family, and is indicated in treating serious infections due to susceptible strains of pathogens. It is often dispensed as an aid for preventive and therapeutic treatment of gastrointestinal and respiratory tract infections, caused by florfenicol sensitive micro-organisms such as *Ornithobacterium rhinotracheale*, *Mannheimia haemolytica*, *Pasteurella multocida*, *Haemophilus somnus*, *Enterobacter cloacae*, *Escherichia coli*, *Klebsiella pneumoniae*, *Salmonella typhi*, *Shigella dysenteriae* and *Staphylococcus aureus* (Shin et al. 2005; Marien et al. 2006; Ronette 2012). Florfenicol inhibit the protein synthesis of bacteria by combining simultaneously with the 50S and 70S subunits in the ribosome and abolish the activity of peptidyl transferase. The action of florfenicol is mainly bacteriostatic (McKellar et al. 2004; Khalil et al. 2012; Wang et al. 2012). Prophylactic application of florfenicol during growth period, decrease the mortality rate in chicken. Birds treated with this product show better body weight gains and better feed utilization than non-treated ones. In addition, florfenicol is active at lower concentrations than its structural analogs against a number of bacterial pathogens. It is also effective against many chloramphenicol or thiamphenicol-resistant strains (Lobell et al. 1994; Ronette 2012). In hatcheries, the hygienic process in association with injecting antibiotics into the egg, result in eliminating infection and preventing egg transmission of pathogens. Nevertheless, the application of antibacterial drugs for in ovo administration in chicken eggs still needs to be justified. In this regard, in the present study, we investigated and examined using various dosages of florfenicol solution for in ovo administration in embryonated chicken eggs. We believe that results in this study will contribute to our better understanding of the safety of amphenicol drugs to the bird embryos.

## Materials and Methods

### Hatching eggs

Fertile chicken eggs (Marandi breed) with the average egg-weight of  $46.5 \pm 0.6$ g and with the same age were purchased from a local breeder farm. In this farm, birds were kept and grown up under the standard condition of breeding.

### Drugs

Florfenicol injectable solution was obtained from Erfan Darou Research and Pharmaceutical Company (Serial No. 9005), Iran. Each milliliter of drug contains 300 mg florfenicol. It was diluted in phosphate buffered saline solution. A volume of 0.5 mL of phosphate buffered saline solution with 20 and 30 mg florfenicol was inoculated per Kg egg-weight.

### Experimental protocol

Eggs were incubated at 37.7°C and 60% relative humidity. The eggs were randomly assigned to four equal treatment groups, 10 eggs each, as follows: group 1: no injected group; embryonated eggs do not receive any treatment at all. Group 2: phosphate buffered saline injected group, embryonated eggs were injected with sterile phosphate buffered saline of 0.5 ml/egg into the yolk sac. On day 4 of incubation, the eggs of groups 3 and 4 were treated with florfenicol injectable solution at a dosage of 20 and 30 mg florfenicol per Kg egg-weight, respectively. Embryos received treatment by direct injection into the yolk sac according to the standard techniques (Hamburger 1942). Embryos were re-incubated post-treatment and allowed to develop. The viability of the embryos was checked throughout the incubation period by candling. All embryos were necropsied on day 18 of incubation and examined for macroscopic and microscopic lesions. The treatment protocols and procedures in this study were conducted according to local ethical guidelines, and were approved by the Animal Ethics Committee of the Research Council of Shahid Bahonar University, Kerman, Iran.

### Pathological examination

At the end of the experiment, on day 18, embryos were humanely killed by placing on ice and then the eggs were opened at the wider end (Jacobsen et al. 2012). After washing in normal saline solution, embryos were observed under stereomicroscope to study any gross abnormalities on the external body surface. The membranes and yolk sac were also inspected. Then, the tissues of embryos were dissected out and fixed in 10% neutral buffered formalin. Following routine preparation of tissues, serial sections of paraffin embedded tissues of 5  $\mu\text{m}$  thicknesses were cut using a microtome (Slee-Germany) and stained with hemotoxylin and eosin and studied under light microscope.

### Statistical analysis

Statistical analysis was performed using SPSS version 20. The Chi-Square test was used to determine the significant differences in lesion occurrence between experimental groups. A P-value of  $<0.05$  was considered as statistically significant.

### Results

#### Macroscopic results

The tissues of the embryos were normal in groups 1 and 2 (figure 1). In florfenicol-injected groups (groups 3 and 4) there was not any gross abnormality in the tissues and external body surfaces (figure 2). The obtained tissue samples of these embryos were sent to the pathology laboratory.



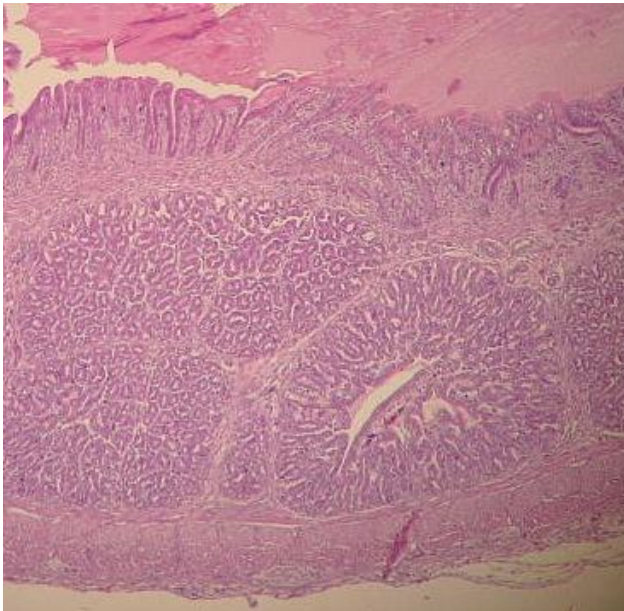
**Fig. 1.** The chicken embryo treated with phosphate buffered saline solution into the yolk sac. The embryo is normal with no gross lesions.



**Fig. 2.** The chicken embryo treated with florfenicol injectable solution into the yolk sac. The embryo is normal with no gross lesions.

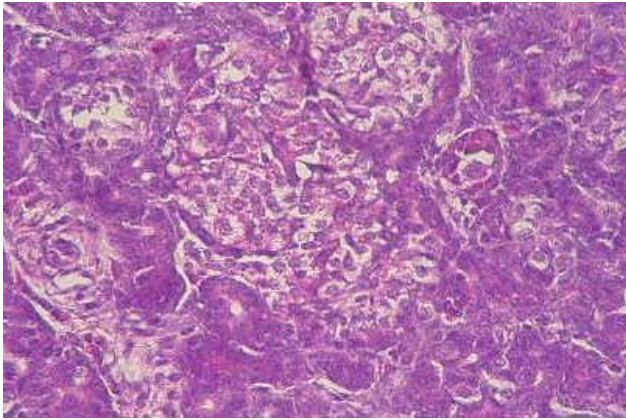
### **Microscopic findings**

Histopathological evaluation has been revealed that all organs were normal in groups 1 and 2. In embryos of groups 3 and 4, which received florfenicol injectable solution, all microscopic structures were also normal (figures 3-5).

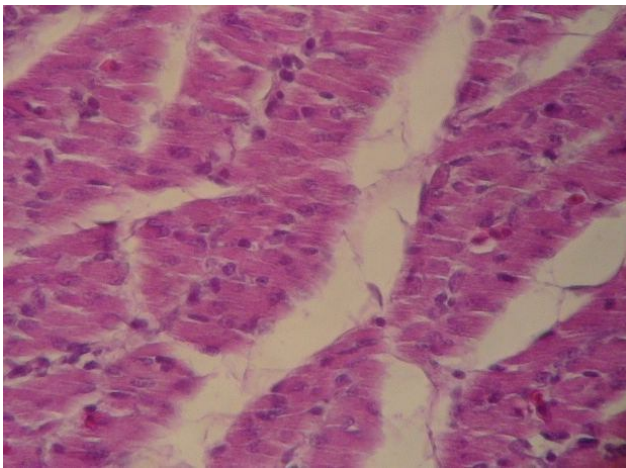


**Fig. 3.** Photomicrograph of the chicken embryo treated with florfenicol injectable solution into the yolk sac. A normal proventriculus tissue is seen.  $\times 40$  H&E





**Fig. 4.** Photomicrograph of the chicken embryo treated with florfenicol injectable solution into the yolk sac. A normal kidney tissue is seen.  $\times 100$  H&E



**Fig. 5.** Photomicrograph of the chicken embryo treated with florfenicol injectable solution into the yolk sac. The normal structure of the muscle is seen.  $\times 400$  H&E

### Discussion

The poultry industry has experienced tremendous development and expansion during the past twenty years. On the other hand, pathogenic agents are an important and significant hazard for poultry health and cause serious economic losses to this industry. For many years, researchers have been using different antibacterial compounds to restrict pathogens and enhance the performance of different poultry species, including young chicken (Colomer-Lluch et al. 2011; Sapkota et al. 2011; Obeng et al. 2012; Banerjee et al. 2013; Tavakkoli et al. 2013), quail (McDougald et al. 2012; Crespo et al. 2013; Rigobelo et al. 2013), turkey (Altunsoy et al. 2011; Erdem and Akova 2012; Buscaglia 2013), broiler (MacDonald and Wang 2011; Agunos et al. 2012; Lee et al. 2012; Tavakkoli et al. 2014), layers (Hasan et al. 2011; Lee et al. 2013; Nemati 2013) and poultry breeder (Kabir 2010; Priyantha et al. 2012; Jones et al. 2013).

Amphenicol drugs have an increased role as therapeutic agents against avian pathogens. They have bacteriostatic effect and a wide antibacterial spectrum. Most gram-positive and gram-negative organisms are susceptible (Sweetman et al. 2009). In many countries such as, United States, Austria, Polish, Canada, Denmark, Germany, Spain, France, Turkey, Africa and China amphenicol compounds have been used successfully for several decades. Florfenicol belongs to the amphenicol pharmacological group and is approved in the European Union for use in cattle, sheep, pigs and chickens (Switała et al. 2007; Ronette 2012). In recent years, its use has increased rapidly in the Iranian poultry industry, but there is little information available about the effects of injecting florfenicol injectable solution into the chicken eggs.

Besides, determining the side effects of drugs on the development of chicken embryo is a useful method for studying the biological properties of drugs. In the present study, we investigated the using and safety of various dosages of florfenicol solution for in ovo administration in chicken egg. Lesions and organ injuries following administration were also inspected.

Up to now, antibiotic-egg-treatment has been examined and described in different situations (McCapes et al. 1977; Ghazikhanian et al. 1980). Some antibiotics such as tylosin and gentamicin were effective in reducing egg-transmission of infection (Nascimento et al. 2005). Tylosin was used because of its efficiency against mycoplasmas and gentamicin was used because of its broad-spectrum activity against bacteria and its low toxicity to host cells. Dosage and the rout of injection can have an influence on the outcome. For example, tylosin can be toxic for eggs when used in high doses (Nascimento et al. 2005). On the other hand, some injection sites that are present in fertile eggs at day 4 of incubation are the air cell and yolk sac. Antibiotics injection into the air cell of the egg is discontinued and is not suitable for breeding purposes because drastic mortality of embryos occur when eggs treat by this procedure (McCapes et al. 1977; Nascimento et al. 2005).

Our results obviously showed no gross abnormality on the external body surfaces of embryos exposed to various dosages of the florfenicol solution by yolk sac rout. Histopathological examination has also been revealed that all organs were normal in embryos. Therefore, these results suggest that the best florfenicol injection sites in ovo may be the yolk sac. Nevertheless, further efforts are needed to evaluate in ovo administration of various amphenicol drugs for prevention and eliminate pathogenic microorganisms.

In conclusion, based on macroscopic and microscopic findings, it is concluded that florfenicol solution can be used for the success of the eradication scheme with low toxicity to chicken embryo. In addition, the yolk sac is an appropriate site for injecting antibacterial drugs.

#### Acknowledgment

The authors wish to thank Mr. S. Hasanzadeh for his kind cooperation in slide preparation.

#### References

- Agunos A, Léger D, Carson C (2012). Review of antimicrobial therapy of selected bacterial diseases in broiler chickens in Canada. *CVJ*. 53(12): 1289- 1296.
- Altunsoy A, Aypak C, Azap A, Ergönül Ö, Balık İ (2011). The impact of a nationwide antibiotic restriction program on antibiotic usage and resistance against nosocomial pathogens in Turkey. *Int. J. Med. Sci.* 8(4): 339.
- Banerjee S, Mukhopadhyay SK, Ganguly S (2013). Phytogetic Growth Promoter as Replacers for Antibiotic Growth Promoter in Poultry Birds. *J. Anim. Gen. Res* 1(1): 6-7.
- Buscaglia C (2013). Influence of the addition of antibiotics on survival of herpevirus of turkeys. *Avian Dis.* 52(2): 437-436.
- Colomer-Lluch M, Imamovic L, Jofre J, Muniesa M (2011). Bacteriophages carrying antibiotic resistance genes in fecal waste from cattle, pigs, and poultry. *Antimicrob. Agents Chemother.* 55(10): 4908-4911.
- Crespo R, Shivaprasad H, Silva Franca M (2013). Ulcerative Enteritis-like Disease Associated with *Clostridium sordellii* in Quail. *Avian Dis.* 57(3): 213-221.
- Erdem H, Akova M (2012). Leading infectious diseases problems in Turkey. *Clin. Microbiol. Infect.* 18(11): 1056-1067.
- Garner DL, Evans KM, Seidel GE (2013). Sex-Sorting Sperm Using Flow Cytometry/Cell Sorting. *Methods Mol. Biol.* 927: 279-295.
- Gharaibeh S, Al-Rashdan M (2011). Change in antimicrobial susceptibility of *Mycoplasma gallisepticum* field isolates. *Vet. Microbiol.* 150(3): 379-383.

- Ghazikhanian GY, Yamamoto R, McCapes R, Dungan WM, Larsen C, Ortmayer H (1980). Antibiotic Egg Injection to Eliminate Disease II. Elimination of *Mycoplasma meleagridis* from a Strain of Turkeys. *Avian Dis.* 24(1): 48-56.
- Hamburger V (1942). A manual of experimental embryology, University of Chicago Press Chicago.
- Hasan B, Faruque R, Drobni M, Waldenström J, Sadique A, Ahmed KU, Islam Z, Parvez MH, Olsen B, Alam M (2011). High prevalence of antibiotic resistance in pathogenic *Escherichia coli* from large- and small-scale poultry farms in Bangladesh. *Avian Dis.* 55(4): 689-692.
- Jacobsen ID, Große K, Hube B (2012). Embryonated Chicken Eggs as Alternative Infection Model for Pathogenic Fungi. *Host-Fungus Interactions. Methods Mol. Biol.* 845: 487-496.
- Jones K, Thornton J, Zhang Y, Mauel M (2013). A 5-year retrospective report of *Gallibacterium anatis* and *Pasteurella multocida* isolates from chickens in Mississippi. *Poult. Sci.* 92(12): 3166-3171.
- Kabir S (2010). Avian colibacillosis and salmonellosis: a closer look at epidemiology, pathogenesis, diagnosis, control and public health concerns. *Int. J. Environ. Res. Public. Health* 7(1): 89-114.
- Khalil S, Hamed E, Hassanin O (2012). Residue Withdrawal of Florfenicol from the Serum and Edible Tissues of Broiler Chickens. *J. Am. Sci.* 8(12): 112-123.
- Lee K-W, Ho Hong Y, Lee S-H, Jang SI, Park M-S, Bautista DA, Donald Ritter G, Jeong W, Jeung H-Y, An D-J (2012). Effects of anticoccidial and antibiotic growth promoter programs on broiler performance and immune status. *Res. Vet. Sci.* 93(2): 721-728.
- Lee S-K, Chon J-W, Song K-Y, Hyeon J-Y, Moon J-S, Seo K-H (2013). Prevalence, characterization, and antimicrobial susceptibility of *Salmonella Gallinarum* isolated from eggs produced in conventional or organic farms in South Korea. *Poult. Sci.* 92(10): 2789-2797.
- Lobell R, Varma K, Johnson J, Sams R, Gerken D (1994). Pharmacokinetics of florfenicol following intravenous and intramuscular doses to cattle. *J. Vet. Pharmacol. Ther.* 17: 253-258.
- MacDonald JM, Wang S-L (2011). Foregoing sub-therapeutic antibiotics: The impact on broiler grow-out operations. *App. Eco. Perspect. Policy.* 33(1): 79-98.
- Marien M, Nauwynck H, Duchateau L, Martel A, Chiers K, Devriese L, Froyman R, Decostere A (2006). Comparison of the efficacy of four antimicrobial treatment schemes against experimental *Ornithobacterium rhinotracheale* infection in turkey poults pre-infected with avian pneumovirus. *Avian Pathol.* 35(3): 230-237.
- McCapes R, Yamamoto R, Ghazikhanian G, Dungan W, Ortmayer H (1977). Antibiotic Egg Injection to Eliminate Disease I. Effect of Injection Methods on Turkey Hatchability and *Mycoplasma meleagridis* Infection. *Avian Dis.* 21(1): 57-68.
- McDougald L, Abraham M, Beckstead R (2012). An Outbreak of Blackhead Disease (*Histomonas meleagridis*) in Farm-Reared Bobwhite Quail (*Colinus virginianus*). *Avian Dis.* 56(4): 754-756.
- McKellar Q, Sanchez Bruni S, Jones D (2004). Pharmacokinetic/pharmacodynamic relationships of antimicrobial drugs used in veterinary medicine. *J. Vet. Pharmacol. Ther.* 27(6): 503-514.
- Nascimento ER, Pereira V, Nascimento M, Barreto M (2005). Avian mycoplasmosis update. *Revista Brasileira de Ciência Avícola.* 7(1): 1-9.
- Nemati M (2013). Antimicrobial resistance of *porteus* isolates from poultry. *Eur. J. Exp. Biol.* 3(6): 499-500.
- Obeng AS, Rickard H, Ndi O, Sexton M, Barton M (2012). Antibiotic resistance, phylogenetic grouping and virulence potential of *Escherichia coli* isolated from the faeces of intensively farmed and free range poultry. *Vet. Microbiol.* 154(3): 305-315.
- Priyantha M, Vipulasiri A, Gunawardana G (2012). *Salmonella* control in poultry breeder farms in Sri Lanka: Effects of oral antibiotic treatment on whole blood agglutination test with *Salmonella pullorum* antigen. *Int. J. Livestock Product.* 3(2): 21-24.
- Rigobelo EC, Blackall PJ, Maluta RP, Ávila FAd (2013). Identification and antimicrobial susceptibility patterns of *Pasteurella multocida* isolated from chickens and Japanese quails in Brazil. *Braz. J. Microbiol.* 44(1): 161-164.

- Ronette G (2012). Pharmacokinetics and Bioequivalence of Florfenicol Oral Solution Formulations (Flonicol® and Veterin® 10%) in Broiler Chickens. *J. Bioequivalence & Bioavailability* 4(1): 1-5.
- Sapkota AR, Hulet RM, Zhang G, McDermott P, Kinney EL, Schwab KJ, Joseph SW (2011). Lower prevalence of antibiotic-resistant enterococci on US conventional poultry farms that transitioned to organic practices. *Environ. Health Perspect.* 119(11): 1622-1629.
- Shin SJ, Kang SG, Nabin R, Kang ML, Yoo HS (2005). Evaluation of the antimicrobial activity of florfenicol against bacteria isolated from bovine and porcine respiratory disease. *Vet. Microbiol.* 106(1): 73-77.
- Swayne D, Glisson JR, McDougald L, Nolan LK, Suarez DL, Nair VL (2013). *Diseases of Poultry*, Wiley-Blackwell.
- Sweetman SC, Pharm B, PharmS F, Eds. (2009). *Martindale: The Complete Drug Reference*. London, Pharmaceutical Press.
- Switała M, Hrynyk R, Smutkiewicz A, Jaworski K, Pawlowski P, Okoniewski P, Grabowski T, Debowy J (2007). Pharmacokinetics of florfenicol, thiamphenicol, and chloramphenicol in turkeys. *J. Vet. Pharmacol. Ther.* 30(2): 145-150.
- Tavakkoli H, Derakhshanfar A, Gooshki SN (2013). A short preliminary experimental study on teratogenic effect of methenamine in embryonic model. *IJABBR.* 1(12): 1523-1528.
- Tavakkoli H, Derakhshanfar A, Salandari S (2014). Investigation on the using of linco-spectin solution for in ovo administration in chicken embryo. *IJABBR.* 2(1): 110-116.
- Tavakkoli H, Derakhshanfar A, Salandari S (2014). Toxicology of urotropine in chicken embryo model. *OJVR.* 18(2): 109-115.
- Wang GY, Tu P, Chen X, Guo YG, Jiang SX (2012). Effect of three polyether ionophores on pharmacokinetics of florfenicol in male broilers. *J. Vet. Pharmacol. Ther.* 35(5): 494-501.