



IJABBR- 2014- eISSN: 2322-4827

International Journal of Advanced Biological and Biomedical Research

Journal homepage: [www.ijabbr.com](http://www.ijabbr.com)



## Original Article

### Effects of the Methanolic Extract of *Abelmoschus Esculentus* (L) Moench (Okro) Fruit on the Testes and Sperm Characteristics of Male Albino Wistar Rats

Nwoke Kyrian Uchenna\*, Konyefom Godswill Nweze, Ifedi Izuchukwu Charles

Department of human physiology Faculty of Basic Medical Sciences, College of Health sciences, University of Port Harcourt, Port Harcourt Nigeria

#### ARTICLE INFO

##### Article history:

Received: 02 August, 2014

Revised: 26 August, 2014

Accepted: 18 September, 2014

ePublished: 30 October, 2014

##### Key words:

*Abelmoschus*

*esculentus*

Gossypol

Hormone, Infertility

Testes

#### ABSTRACT

**Objective:** In this study aimed at evaluating the antifertility effect of the methanolic extract of *Abelmoschus esculentus* (okro) fruit using albino wistar rat. **Methods:** Fifty adult male rats weighing 200g to 300g were weighed and divided into five groups of five rats each. Group 1 served as the control and were given water and normal rat chaw while groups 2, 3, 4 and 5 served as the test groups and were orally administered with (250, 500, 750 and 1000)mg/kg of okro extract respectively after three weeks of acclimatization. Following six weeks of extract administration, the rats were reweighed and sacrificed. Semen was collected from their caudal epididymis for sperm analysis and their testes were weighed and processed for histological studies. **Results:** Results from the test groups showed a significant ( $p \leq 0.05$ ) reduction in the testicular weight and a significant ( $p \leq 0.05$ ) increase in the body weight of the rats when compared with the control group. There was also a significant ( $p \leq 0.05$ ) decrease in sperm count and sperm motility with a corresponding increase in the percentage number of abnormal sperm cells. The histology of the testes showed degenerating testicular tissues. From the result, we therefore conclude that consistent consumption of okro may be destructive to the testes and as such, could impair male fertility.

## 1. INTRODUCTION

A marked decrease in the quality and quantity of semen seen in the last few years has become a source of worry to all. This has been reported to contribute to about 40-50% cases of infertility around the world (Brugh and Lipshult 2004). The cause of this ugly trend has been traced to certain factors that could interfere with spermatogenesis and reduce sperm quality and production. Some of the identified factors are lifestyle, environmental factors, occupational hazards and anatomical/physiological abnormalities (Sinclair, 2000). Also, some herbs and fruits use for food and medicine

have been implicated in this ugly trend. Some of the herbs documented are *cannabis sativa* (Dioscorides ca. 40 A.D), *sarcostemma acidum* (Venma et al., 2002), neem tree (Deshpande et al., 1980), *carica papaya* fruit (Lohiya et al., 2002) and oil from cotton seed (Hadley et al., 1981).

Recently, the oil present in cotton seed (gossypol) has been also reported to be present in *abelmoschus esculentus* (okro) fruit. This plant fruit is a widely cultivated in the tropical and warm temperate regions of the world; and it is eaten because it is abundant with so many important minerals and vitamins (El-Malak, 2007). Apart from this, a wide range of medicinal values have

\*Corresponding Author: Nwoke Kyrian Uchenna, Department of human physiology Faculty of Basic Medical Sciences, College of Health sciences, University of Port Harcourt, Port Harcourt Nigeria ([nwokekyrian@yahoo.com](mailto:nwokekyrian@yahoo.com))

also been reported on okro fruit. On its antioxidant activity, Yan reported that it has a high super oxide scavenging activity (Yang et al., 2006) while Kahlon reported that extracts from okro fruit effectively lowered blood cholesterol level in rats on the account of its high viscous fibre content (Kahlon et al., 2007b) Okro extracts have also been shown to inhibit 5-lipoxygenase and hence inhibit inflammation in vivo (Sekiya, 1997). Other studies have also reported the antiulcerogenic, antidiabetic, antiproliferative and proapoptotic effects of the extract of okro fruits (Lengsfeld et al., 2004; Sabitha et al., 2011; Dan and Gu, 2010; Vayssade et al., 2010). The study of the extract of the fruit in male reproductive system has been very scanty. However, Olatunji-Bello et al., (2009) in their study reported that the aqueous extract of okro fruit significantly ( $P \leq 0.05$ ) decreased the mean weight of the testes of the rats treated for 28 days. This present study therefore ascertains the effect of the methanolic extract of okro fruit in the testicular weight and histology of male albino wistar rats; we also evaluate its effect on the sperm characteristics of the rats. We have also set the following objectives in this study:

- To evaluate the effect of okro extract on the body weight and organ (testes) weight of male rats
- To evaluate its effect on the motility and morphology of sperm cells
- To determine its effect on the total sperm count
- To evaluate its effect on the histology of the testes

Therefore, this study will throw more light on the reproductive safety of okro fruit and will provide an insight into the role of okra fruit in the etiology of male infertility. At the same time, the study will drive knowledge in to the possibility of using natural food for birth control instead of the invasive method usually used in males. Also, this study will be helpful to fertility counsellors in recommending diets for couples seeking conception; and inform newly married ladies on the type of food to remove from their menu.

## 2. MATERIALS AND METHODS

### 2.1. Procurement and Preparation of Experimental Animals

Twenty five (25) adult male albino wistar rats weighing 200-260gms were acquired from a private breeder in Port Harcourt Nigeria and housed in a clean wooden cage lined with saw dust at the animal house of the Department of Human Physiology, Faculty of Basic Medical Sciences, College of Health Sciences, University of Portharcourt, Nigeria. Standard room temperature of 25-30°C, humidity of 60-70% were maintained and the rats were allowed natural light-dark cycle with free

access to rat chaw from livestock feeds limited, Sapele Nigeria and normal tap water at libitum. The rats were allowed to acclimatize under this condition for three weeks (21 days). International guidelines for the care and use of laboratory animals in biomedical research as recommended by the Canadian council of animal care (CCAC, 1985), and the recommendation of the guiding principles in the care and use of animals for research were adhered to, in the course of this study.

### 2.2. Plant Material and Preparation of Extract

Fresh fruits of *Abelmoschus esculentus*(okra) were purchased from mile three market in Port Harcourt Nigeria and were identified by DR. N.L.EDWIN-NWOSU of the Department of Plant Science and Biotechnology of the University. The specimen were documented and preserved at the University of Port Harcourt herbarium with the reference number UPH/PSB/016. The okra fruits were washed and air dried under shed to become bristle. 3kg of the fruit was ground to powdered form using manual grinding machine. 500gms of the powdered fruit was then soaked in 99% methanol at 60-70°C for 36 hours in continues extraction using soxhlet apparatus. The resultant extract was filtered and concentrated under reduced pressure at 40% using rotary evaporator. The dark-brown jelly yield was then stored in an air-tight bottle and preserved in a refrigerator at -4°C, pending usage. The stock solution was thereafter prepared by dissolving 10gms of the extract in 100ml of distilled water. Water was used because it was discovered that the extract is very soluble in water. The volume of the stock given to each animal was calculated using the modified formula below.

$$\text{Vol. (ml)} = \text{dose of extract (mg.kg}^{-1}) \times \text{weight of the rat (kg)} / \text{conc. of stock (mg/ml)}$$

### 2.3. Experimental Design

After acclimatizing the 25 male rats for 21 days, they were weighed divided into 5 groups of 5 rats each according to their weights. Group1 served as the control group and was administered with 1ml of water orally while groups 2, 3, 4 and 5 received oral administration of okra extract at 250mg/kg, 500mg/kg, 750mg/kg and 1000mg/kg respectively and served as the test groups. After six weeks (42 days) of treatment, on the 43<sup>rd</sup> day, the rats were reweighed and sacrificed.

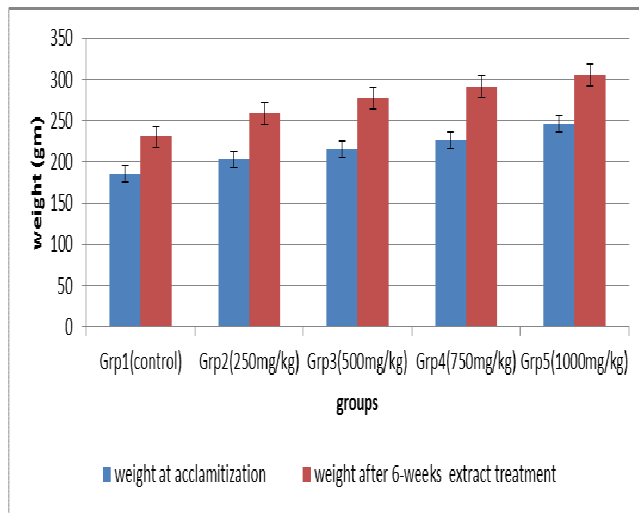
### 2.4. Assessment of Experimental Parameters

Sperm was collected by scrotal incision to expose the testes with the epididymis and vas deference, sperm was then gently squeezed out from the tail of the epididymis through the vas deference into a Petri dish and following following WHO outline as contained in WHO protocol MB-50 (W.H.O, 2010). Total sperm count, Sperm motility and Sperm morphology were analyzed. The

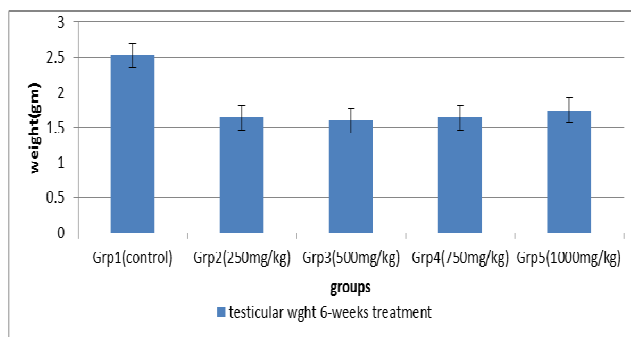
testes with the epididymis were weighed using a digital weighing balance and then fixed in 10% formalin for histological studies following the basic histological techniques.

### 3. RESULTS AND DISCUSSION

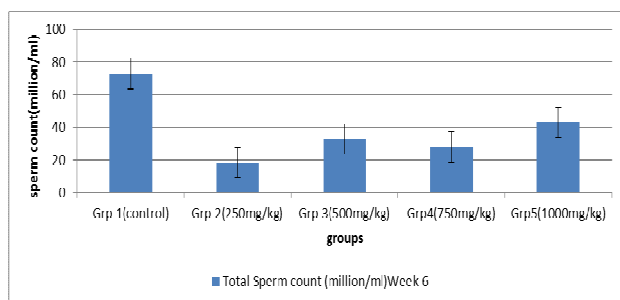
At the end of the study, analyzed results are as shown in the figures below.



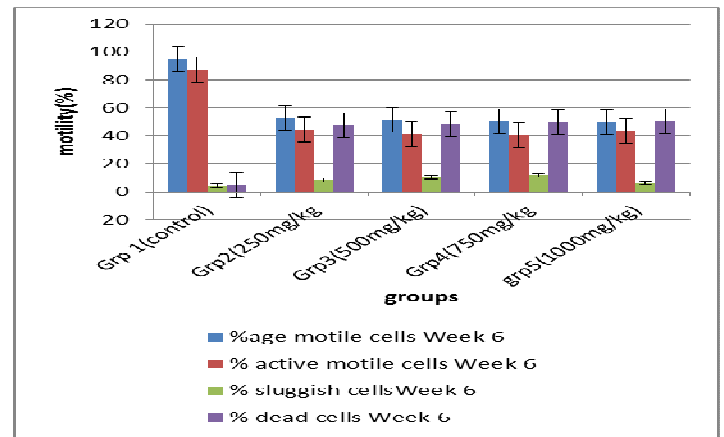
**Figure1.** showing the effect of okro extract on the rats' body weight



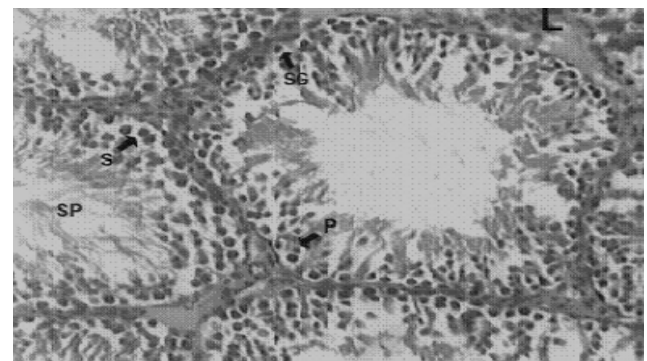
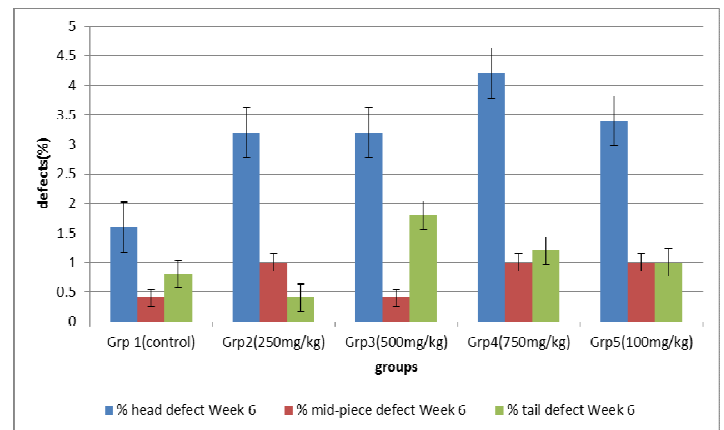
**Figure2.** showing the effect of okro extract on testicular weight



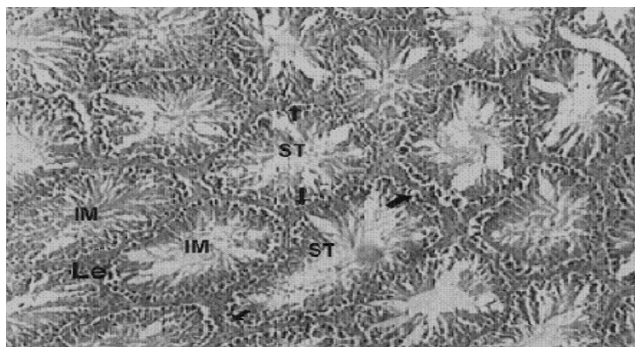
**Figure3.** showing the effect of okro extract on total sperm count



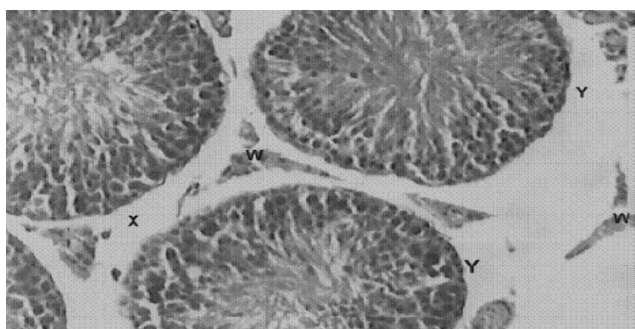
**Figure4.** showing the effect of okro extract on sperm motility



H&E Stain Mag. X400. figure 6 (control): Section showing the histology of the rats' testis with normal arrangement of the spermatogenic features P =primary spermatocytes; SG = spermatogonia, S = sertoli cells, L = Leydig cells; Sp = spermatids and spermatozoa



H&E Stain Mag. X400. figure 7 (750mg/kg): Section showing the histology of the rats' testis with irregularly shaped seminiferous tubules (ST), immature spermatozoa (IM) and less Leydig cells (Le)



(H & E stain x 400).figure 8 (1000mg/kg): showing the histology of the rats' with degeneration of interstitial tissues (x), loss of Leydig cells (w) and seminiferous tubules appear as isolates (Y).

**Figure5.** showing the effect of okro extract on sperm morphology

## CONCLUSION AND RECOMMENDATIONS

We have observed in this study that the methanolic extract of okro fruits decreases the weight of the testes and causes degeneration of the testicular tissues (seminiferous tubules and sertoli cells). Also, considering the effect of the extract on the sperm characteristics (count, motility and mophorlogy), it could be concluded that consistent consumption of meals of okro fruit may have a deleterious effect on male reproductive parameters and is capable of causing infertility in male rats. This conclusion is in concordance with the one made by Olatunji-Bello *et al.* in 2009 on the same fruit [15]. However, further prolonged studies of 90 to 120 days of administration of the extract should be carried out to determine the effect of the extract on the serum concentration of male reproductive hormones and male reproductive behaviours.

## ACKNOWLEDGEMENT

The satisfaction that accompanies the successful completion of this work would have been next to impossible without the mention of the people whose

consistent support, guidance and encouragement crowned my effort with success. In a special way we thank Mr. Chijioke Nwoke for his financial and moral support all throughout this work we also thank Peter, Linder and Chibuzor for their relentless encouragements. We feel honoured to express our profound regards and deep sense of gratitude to my supervisor Dr. Mrs. F.S. Amah-Tariah for her motherly guidance all through this work. we am highly obliged and grateful for her excellent guidance and the unique cooperation extended to us, right from the onset of the task till its successful completion. Our sincere gratitude goes to Dr. Olorunfemi O.J. the Coordinator of graduate studies Department of Human Physiology, University of Port Harcourt, Nigeria. And to all who directly or indirectly contributed in the development of this work; people like Mr. Okoli Chinweike, Miss Bethy Bassy, Miss Blessing David, Miss Abiye Amadi, Mr. Bekinbo Mpakaboari and Mr. Nwafor Charles. At last, we thank the Almighty God for all the blessings bestowed on us.

## REFERENCES

- Brugh VM, Lipshultz LI (2004). "Male factor infertility". *Medical Clinics of North America* **88** (2): 367-85.
- Canadian Council of Animal Care (CCAC), (1985). *Guide to the handling and use of experimental animals*. Ottawa: ont; 2 United States NIH publications, No. 85-230:45-47.
- Dan R.D. and Gu C, (2010). Inhibition Effect of Okra Polysaccharides on Proliferation of Human Cancer Cell Lines. *Journal Food science*, 21.
- Deshpande V.Y, Mendulkar K.N, Sadre N.L (1980). "Male antifertility activity of Azadirachta Indica in mice". *Journal of Postgraduate Medicine* **26** (3): 167-70.
- Dioscorides (ca. 40 A.D.). *De Materia Medica*. (translated by Goodyer (1655), modified and published 1933 by Robert Gunther).
- El-Malak G.A.A., (2007). Evaluation of free radical scavenging by natural antioxidants in some fresh, blanched, cold and frozen storage of vegetables. *Annals of Agricultural Science (Cairo)*, 52(2): 367-374.
- Hadley MA, Lin YC, Dym M. (1981). "Effects of gossypol on the reproductive system of male rats". *J Androl.* (2): 190-9.
- Kahlon T.S, Chiu M.C.M, Chapman M.H (2007b). Steam cooking significantly improves in vitro bile acid binding of beets, eggplant, asparagus, carrots, green beans, and cauliflower. *Nutrition Research*, 27(12): 750-755.
- Lengsfeld C, Titgemeyer F, Faller G, Hensel A (2004). Glycosylated compounds from okra inhibit adhesion of

*Helicobacter pylori* to human gastric mucosa. Journal of Agricultural and Food Chemistry, 52(6): 1495-1503.

Lohiya NK, Manivannan B, Mishra PK et al. (2002). "Chloroform extract of *Carica papaya* seeds induces long-term reversible azoospermia in langur monkey". Asian J Androl. 4 (1): 17-26.

Olatunji-Bello I.I., Ijiwole, T. Fawobajo.O.(2009). Evaluation of the Deleterious Effects of Aqueous Fruit Extract of *Abelmoschus Esculentus* (Okro Fruit) on Some Male Reproductive Parameters in Sprague Dawley Rats; Journal of Phytology, Vol 1, No 6

Sabitha V., Ramachandra S., Naveen K.R., and Panneerselvam (2011). Antidiabetic and Antihyperlipidemic potential of *Abelmoschus esculentus*(L) Moench. in streptozotocin-induced diabetic rats. Journal of pharmacy and bioallied sciences 3(3):397-402.

Savello P.A., Martin F.W. and Hill J.M (1980). Nutritional composition of okra seed meal, Journal of Agric food chemistry, 28(6): 1163-1166.

Sekiya K (1997). Inhibition of cyclooxygenase and lipoxygenase by foods. Bulletin of the Shikoku National Agricultural Experiment Station, No. 61: 31-37.

Sinclair S., (2000). Male infertility: nutritional and environmental consideration: alternative medicine review 5: 28-38.

Vaysade M., Sengkhampan N., Verhof R., Delaigue C., Oundiam O., Vingneron P., Voragen A.G.J., Schols H.A. and Nagel M.D, (2010). Antiproliferative and Proapoptotic Actions of Okra Pectin on B16F10 Melanoma Cells, Phytotherapy Research journal, 24(7): 982-989.

Venma P.K, Sharma A, Mathur A et al. (2002). "Effect of *Sarcostemma acidum* stems extract on spermatogenesis in male albino rats". Asian Journal of Andrology 4 (1): 43-7.

W.H.O. (2010). Laboratory manual for the examination and processing of human semen 5th ed. WHO Press World Health Organization, 20 Avenue Appia, 1211 Geneva 27, Switzerland;7-113.

Yang R.Y, Tsou SCS, Lee T.C, Wu W.J, Hanson P.M, Kuo G, Engle L.M, Lai P.Y (2006). Distribution of 127 edible plant species for antioxidant activities by two assays. Journal of the Science of Food and Agriculture, 86(14): 2395-2403.